

Neuropsychological features of rapidly progressive dementia in a patient with an atypical presentation of Creutzfeldt-Jakob Disease

Maria Pąchalska¹, Henryk Kurzbauer², Bruce Duncan MacQueen³, Maria Formińska-Kapuścik⁴, Irena Herman-Sucharska⁵

¹ Department of Medical Rehabilitation, Cracow Rehabilitation Center, Cracow, Poland

² Department of Neurology, MSWiA Hospital, Cracow, Poland

³ Department of Neurolinguistics, Rydygier Medical University, Bydgoszcz, Poland

⁴ Department and Clinic of Ophthalmology, Silesian Medical University, Katowice, Poland

⁵ Magnetic Resonance Laboratory, Department of Radiology, University Hospital, Cracow, Poland

key words: spongiform encephalopathy, Creutzfeldt-Jakob Disease - Heidenhain variant, dementia, hallucinations, agraphia

SUMMARY

Background. Creutzfeldt-Jakob Disease (CJD) is a degenerative disease of the brain, characterized by rapid and irreversible decline, with dementia, ataxia, myoclonus, and other neurological and neurobehavioral disorders associated with rapidly progressive spongiform encephalopathy. The mode of transmission and basic pathomechanism remain unclear. The clinical picture of CJD is highly diverse, producing a number of variants.

Material and methods. The patient to be described is a 68-year-old Polish female, JR, clinically diagnosed with CJD. The article presents the case history in detail, with particular emphasis on neuropsychological testing, which was initiated when the patient was still lucid and capable of cooperation. The first presenting symptom was agraphia, followed by hemianopsia and other vision disorders, culminating in visual hallucinations. As the progress of the disease accelerated there was rapidly progressive dementia, aphasia developing to organic mutism, myoclonus, hyperkinesia, ultimately loss of all verbal contact or voluntary movement.

Results. JR's neuropsychological parameters declined in a period of less than 3 months from near normal to levels characteristic of severe dementia.

Conclusions. The clinical picture here presented is consistent with that of the Heidenhain variant of CJD, with spongiform encephalopathy beginning in the right occipital lobe. Several features of the case remain atypical, however, including the absence of the most common genetic mutation and the patient's long survival after onset.

BACKGROUND

Spongiform encephalopathy (SE) in various forms occurs in many degenerative diseases of the central nervous system, including Alzheimer's Disease, a number of mitochondrial cytopathies [1], and the prion diseases that have recently been attracting so much attention in Europe and elsewhere [2,3]. The name is derived from the prominent vacuolation of the gray matter of the brain, producing a 'spongelike' appearance on light microscopy [4].

The clinical symptoms associated with SE are typically of insidious onset, due to the cumulative effect of neuronal loss without organized areas of necrosis visible in normal neuroimaging scans [5,6]. Complex cerebral functions involving the cooperation of numerous neural centers and pathways [7] are naturally the most vulnerable to this kind of damage, which explains why the leading symptom is typically dementia, sometimes preceded, followed, or accompanied by a variety of other neurological and neurobehavioral

Received: 2001.08.09

Correspondence address: Prof. Maria Pąchalska, MD, PhD, ul. Imbramowska 1/34, 31-212 Kraków, POLAND, tel./fax (+48 12) 425-28-33,

Accepted: 2001.08.20

ext. 214, e-mail: athene@poczta.onet.pl

disturbances, including ataxia, myoclonic seizures, and psychosis. For reasons that remain unclear, the degenerative process associated with SE typically begins at a particular point in the brain and spreads outward [4,8,9], so that the nature and course of the CNS symptoms associated with SE seem to be related to the initial point of attack and the rate of dissemination [8,10].

Of the various diseases caused by or causing spongiform encephalopathy, the prion diseases are perhaps the most interesting, and surely the most controversial. A prion is a transmissible pathogen that is neither a bacterium nor a virus, but rather a protein (PrP), lacking any replicative elements. The term was coined by Stanley Prusiner [11], whose discovery of prions won him the Nobel Prize for medicine in 1997. The PrP protein is genetically coded by the PRNP gene in the human chromosome. It occurs primarily in the central nervous system, but its exact function remains unknown [12–14]. Pathogenic prions (PrP^{Sc}) are biochemically configured in such a way that they attach to normal PrP molecules (PrP^C) and transform them into the PrP^{Sc} configuration, which differs from PrP^C in its almost complete lack of susceptibility to protease [4,15]; the proliferation of PrP^{Sc} leads to cell death and SE, though exactly how and why this occurs remains unclear.

Apart from the various known animal diseases known or thought to be linked to prions (including especially bovine spongiform encephalopathy, BSE), there exists also an entire array of phenotypically distinct human prion diseases [16], varying in course and (probable) mode of transmission, of which the most notorious is Creutzfeldt-Jakob Disease (CJD), characterized by rapidly progressive severe dementia, ataxia, myoclonus, and hyperkinesia. CJD typically has a very long incubation period (up to 20 years [4]), but after the first clinical symptoms appear the patient enters into an irreversible rapid decline, ending in death.

Several variants of CJD have thus far been identified:

- sporadic (sCJD), occurring in patients older than 60, the form originally identified by Creutzfeldt [17] and Jakob [18];
- familial (fCJD), a genetically transmitted form [19,20];
- iatrogenic (iCJD), mostly traceable to neurosurgical procedures [21,22] or injections of human

growth factor [23,24,25], or various kinds of hormones from untested sources [26,27];

- new variant (nvCJD), which appears to be a transmissible human form of bovine spongiform encephalopathy (BSE), the famous ‘mad cow’ disease [28,29];
- the Heidenhain variant (HvCJD), probably a form of sCJD in which vision disturbances are the first presenting symptoms [30,31].

As in the case of Alzheimer’s Disease, the diagnosis of CJD cannot be definitively established until neuropathological autopsy results have revealed the characteristic findings (esp. SE, amyloid plaques without the characteristic neurofibrillary tangles of Alzheimer’s Disease, etc.). The presence of protein 14-3-3 in cerebro-spinal fluid is fairly specific for CJD, with some differences among the variants [32]; for example, all published cases of HvCJD to date have been positive for 14-3-3 in the CSF [33]. EEG results show certain characteristic features [34], especially periodic or pseudoperiodic paroxysms of triphasic or sharp waves of 0.5 to 2.0 Hz against a slow background [4,35]. Functional imaging technologies (PET, SPECT) that reveal areas of metabolic abnormality in the brain have also proved to be useful in detecting early signs of CJD, when MRI and CT images are normal or at least non-specific [5,10,36].

CASE REPORT

The patient to be described here is a 68-year-old right-handed Polish female, initials JR. She is presently widowed (her husband died of lung cancer in 1990), with children and grandchildren, all healthy. There is no family history of neurological illnesses (migraine, stroke, neuropathy, AD, MS, etc.), and her previous medical history is unremarkable (overweight, mild hypertension controlled by medication, instability of cervical spine, no surgical operations, no hospitalizations apart from childbirth). The family reports that she was never particularly fond of meat dishes and especially disliked beef. As a young woman, however, she worked in a factory that manufactured animal hair brushes for export, so she had contact with animal byproducts (including bovine) and chemical agents of various kinds. Her only foreign travel was a trip to Kiev in 1986, shortly after the Chernobyl explosion. As far as can be ascertained, she was never subjected to hormone therapy, neurosurgery, or other medical procedures known to be risk factors for iCJD.

Disquieting events that in retrospect may be related to the onset of CJD began in early 2000. In March, after a short walk uphill, she suddenly began to sweat profusely, from the head only, though she was not especially fatigued. The sweating subsided within a few minutes and she did not seek medical attention. In June, she was bitten by an insect, probably a mosquito, and developed an abscess, which required outpatient surgery and antibiotics; later, however, she developed severe edema involving the entire left side of her face, though there was no previous history of drug allergy. The family also reports in retrospect that during the summer of 2000 some negative changes took place in her personality. She had always been a warm and kind woman, much

beloved in the family, but during this period she began to be uncharacteristically short-tempered and quarrelsome. She also noticeably lost interest in previous avocations and pastimes.

An examination of her monthly payment book for her apartment shows signs of a sudden change in July (cf. Fig. 1). All earlier entries are uniform in character, legible, and completely routine. In the June entry the letters are slightly larger than usual, but the content is unchanged. In the July entry, however, there are several features that attract notice. To begin with, she has misspelled (telescoped) the word 'seventy', a mistake not made on any previous form. On the reverse, JR has written a calculation of the amount due that month, which also does not occur in any previous month; the family states that she had always been proud of her ability to do arithmetical problems in her head. The notation on the reverse is disorganized, and the phrase 'for the year 1999' at the bottom is highly problematic: she seems to have written the letter 'r' (Polish abbreviation for 'year') twice, then corrected the first 'r' to a 6, which in context is completely unmotivated. The next month, the problems are even more apparent: on the obverse, her signature is in the wrong place and is clearly altered from the previous pattern. This time there are even more mistakes in the sum written out, so that the postal clerk was reluctant to accept the payment. On the reverse, she first wrote 'July' (Polish 'lipiec'), and then corrected to 'August' (sierpień) by simply writing over. The year is given as '20000' (perseveration), and instead of the standard abbreviation 'r' she has written out the word 'rok' ('year'), though it is barely legible. In September, after yet another quarrel with the postal clerk, she asked her son to help her fill out the forms, and from that point on she gradually ceased to take care of her own affairs.

The family was concerned, but attributed the changes to advancing age and stress. Medical attention was not sought until mid-September, when she began to experience vision disorders and reported to an ophthalmologist. Her initial complaint was that objects in the immediate vicinity would suddenly seem to be much closer, or sometimes much farther away, than in fact they were. An ophthalmological examination showed hemianopsia, unaccompanied by pyramidal symptoms. By early October JR had lost all sense of visual perspective, and the visual images also began to be seriously distorted. She first reported

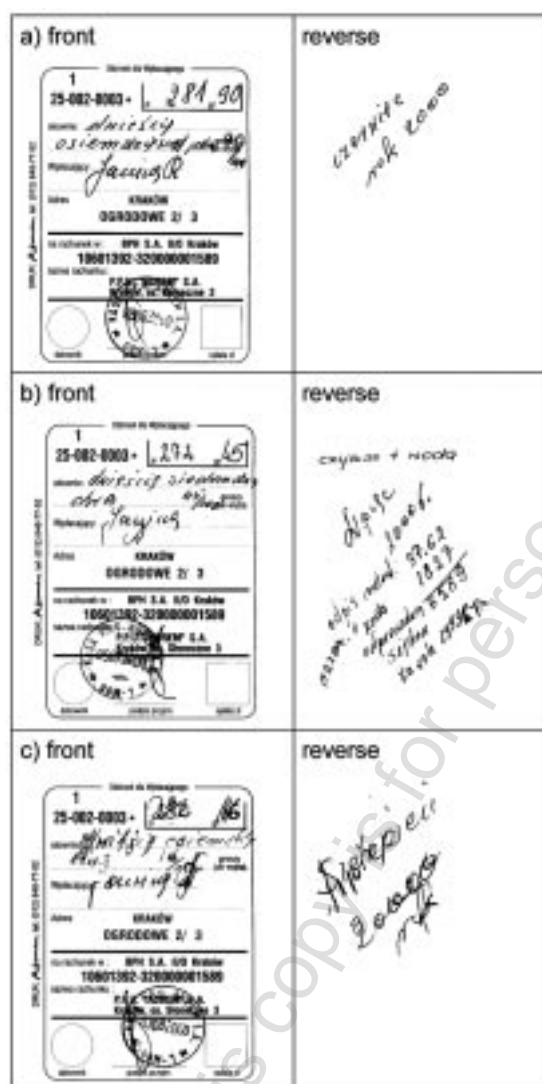


Figure 1. JR's monthly rent payment book for June (a), July (b) and August (c) 2000.

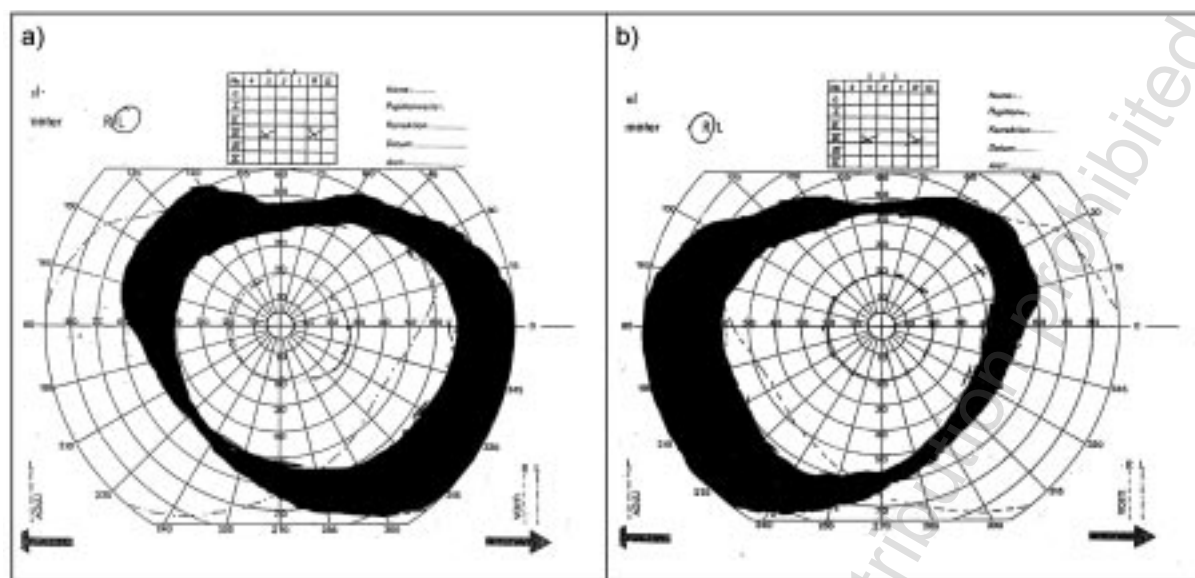


Figure 2. JR's field of vision (November 2, 2000); a) left eye, b) right eye.

that automobiles on the street looked very flat; later, she commented with consternation that her daughter's face was horribly distorted, virtually repulsive, with all the features out of place. She also manifested hypersensitivity to bright colors, especially red, which she avoided (during this period she discarded all her red towels and replaced them with dark blue). In early November a test of her field of vision showed restrictions (cf. Fig. 2), though the hemianopsia had momentarily receded, only to return several weeks later. Her gait had slowed considerably, but she herself attributed this to her difficulties in maintaining visual perspective and anxiety that she would stumble over something. Later, she complained of a feeling that a great precipice was opening before her feet, and if she took one more step forward she would fall into a chasm.

Systematic neuropsychological testing began in early October [37]. The patient did not have aphasia at this point, as shown by a normal score on the Western Aphasia Battery - Revised (WAB-R) [38]. It was noticed, however, that she showed hesitation in some naming tasks, and in ordinary conversation complained of being occasionally unable to recall words; this was reflected in a low-normal score on the Boston Naming Test (BNT) [39]. She had difficulties with simple arithmetical operations and was unable to complete all but the very simplest block pattern tests in the Wechsler Adult Intelligence Scale - Revised [40]. Delayed verbal and visual recall were below normal for her age group on the Wechsler Memory Scale - Revised (WMS-R) [41].

On selected subtests from the Cracow Right Hemisphere Diagnostic Battery [42] her scores were somewhat below normal in the areas of agnosia, constructive apraxia, and apraxism, but not in the range typical for patients with RH strokes. Tests for hemispatial neglect showed a slight tendency to neglect the left side, which on repeated tests became much more pronounced.

By this time she had begun to have hallucinations. In early October she reported seeing black spots before her eyes; by late October the black spots had become insects climbing the walls. She was still aware that these were indeed hallucinations; at times she even joked about them.

In mid-November, in view of worsening problems with her gait and increasing difficulties in coping with daily living she was hospitalized in the Department of Neurology at the Ministerial Hospital of the Polish Ministry of Internal Affairs and Administration (MSWiA) in Cracow. Except for a brief furlough during the Christmas holidays she has been confined to hospital since that time, under the care of the second author of the present article. Her difficulties with naming increased, and she was observed to have growing difficulties with pragmatics: inability to maintain the topic of conversation, violations of turn-taking rules, etc. The family, nursing staff and JR's fellow patients reported an increasing tendency to monologizing. Repeated neuropsychological testing showed declines in virtually all measured parameters, including perseveration (cf. Fig. 3).




Figure 3. Perseveration test (instruction: "Please make five exact copies of the model figure"), mid-November 2000.

An MRI performed after admission showed Virchow perivascular spaces in the vicinity of the medial section of the putamen (on the right side and posterior left), isolated minor hyperintensive foci visible in T2 and FLAIR sequences in the vicinity of the corona radiata bilaterally, and cortical and subcortical cerebral atrophy (esp. the left and right insula, parahippocampal gyrus, and frontal region).

By mid-December JR ceased to be critical of her hallucinations. During this period she showed for the first time a pathological score on the WAB-R, and verbal contact with the examiners began to be difficult. When actively hallucinating she was disoriented and unresponsive. In view of the rapid deterioration the decision was made to test the

patient for possible CJD, and a sample of her CSF was sent to a German laboratory to test for the presence of the 14-3-3 marker protein. An EEG performed at this time revealed periodic triphasic sharp waves, particularly in the occipital lobes, and myoclonus occurring synchronically with generalized periodic epileptiform discharges. Viral encephalitis was definitively excluded by laboratory tests for cytomegalovirus and other encephalitic agents. When the results of the test for 14-3-3 were returned positive, the patient received a clinical diagnosis of CJD, pending neuropathological confirmation of SE.

The tempo of mental and physical deterioration began to accelerate rapidly in mid-December. Neuropsychological testing was possible for the last time just before the Christmas holidays. By this time the patient was bedridden with severe left hemiparesis; visually she reacted only to large, red objects, so the authors adapted a number of tests accordingly to enable her to complete the tasks. She recognized and correctly identified some of the large red cut-out figures, though her verbal output was now scarce and barely audible. When asked to point to specified geometrical figures she was able to comply, though in order to look at the test cards she turned her head sharply to the right and rotated her eyes sharply to the left. She showed severe left-sided neglect in a large-figure (10 cm x 10 cm) cancellation task, which is also apparent in the drawings she made at that time (Fig. 4), at a point when she was still able to hold the pen.

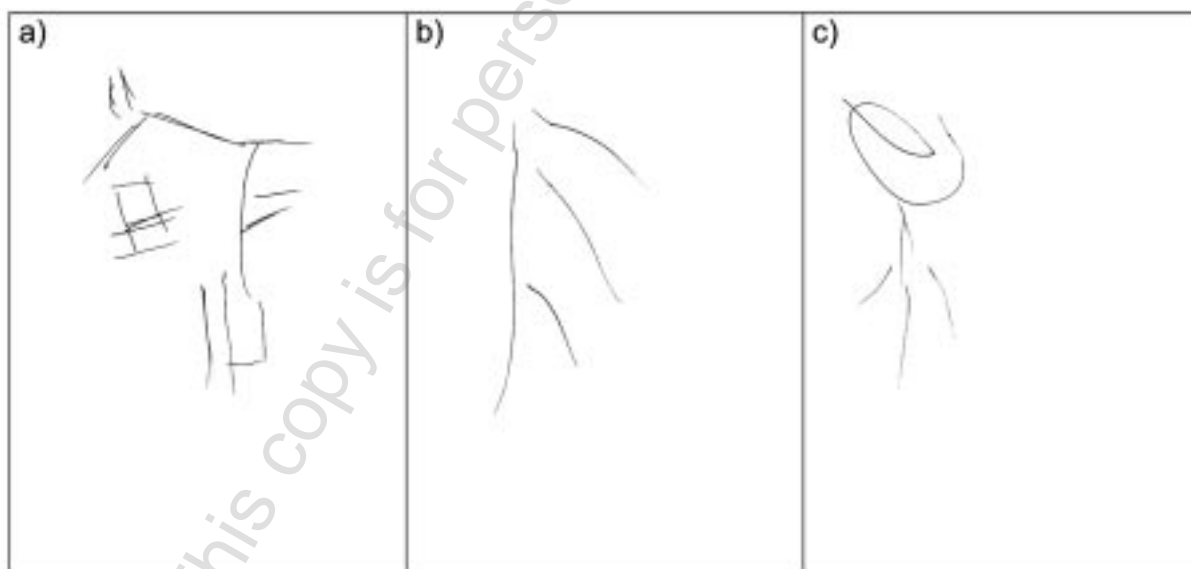


Figure 4. Three drawings made by JR on December 23, 2000, showing hemispatial neglect and constructive apraxia; a) house; b) tree; c) person

In mid-January an effort was made to repeat the MRI examination, but only a few images could be made due to the patient's restlessness and inability to cooperate; nothing remarkable was found. On this occasion the authors were able to evoke no more than three or four words in simple repetition, and by the next day she ceased to speak entirely. For the next few days she was minimally and sporadically responsive to simple verbal commands, but within a week she ceased to show any signs of awareness. Myoclonus and hyperkinesia appeared, and became steadily more intense. JR reacted to sudden noises by slowly raising her right arm after a 1-5 second delay. At such times she often displayed a catatonic reaction: the arm would remain in the position she left it, or in the position given by the therapist, until moved by some outside force. She had sleep-wake cycles and often held her eyes open during the day, but did not follow movements or show any sign of voluntary eyeball movement; rather, her eyes moved in a repetitive symmetric jerking rhythm upwards and to the left. A specialized ophthalmological examination showed cortical blindness with no signs of remarkable ocular pathology.

In view of the typical progress of the disease and the high probability that the diagnosis was accurate, there was a general expectation that death would ensue within the next few days or weeks. However, JR has remained stable in her

present condition since that time, with no significant changes. The hyperkinesia and myoclonus have receded, but not completely disappeared. The jerking eye movements have also ceased, but there is no voluntary eye movement. JR must now be fed by nasogastric tube, since the swallowing reflex has disappeared. Infections have developed on several occasions, but so far, despite her weakened condition, the organism has successfully rallied to defend itself. Occasionally when she is spoken to by her son or daughter tears appear in her eyes, but there is no other reaction to any stimulus or sign of awareness of the environment.

A DNA sample isolated from JR's blood has been tested genetically at the University of California at San Francisco under the supervision of S. Prusiner. To date it has been discovered that the most common mutation associated with CJD, at codon 129, is not present. Further testing is in progress.

RESULTS

Table 1 gives the results of three successive administrations of the neuropsychological tests given to JR during her illness; in order to illustrate the trends graphically, the results for the WAIS-R have also been presented in the form of a graph (see Fig. 5).

Table 1. Results of standard neuropsychological tests in October, November, and December, 2000.

Test	Scale	Examination		
		early October	mid-November	late December
Wechsler Adult Intelligence Scale – Revised				
Verbal	100	97	75	25
Non-verbal	100	95	61	15
Composite	100	96	68	20
Wechsler Memory Scale – Revised				
Immediate logical memory	24	21	15	3
Delayed logical memory	24	20	16	2
Immediate visual recall	41	36	28	5
Delayed visual recall	41	30	22	2
Western Aphasia Battery – Revised				
Aphasia Quotient	100	98	75	22
Cortical Quotient	100	86	55	12
Boston Naming Test				
Anomia score	100	75	45	9
Cracow Right Hemisphere Diagnostic Battery				
Agnosia	100	94	73	12
Constructive apraxia	100	87	41	3
Apragmatism	100	95	59	10
Perseveration	50	45	31	14

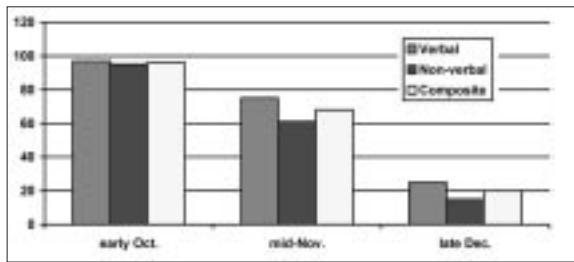


Figure 5. Changes in overall intelligence (WAIS-R) in patient JR between early October and late December of 2000.

The decline in all parameters in all tests is dramatic, and also very nearly parallel. The tendency to lower scores on those elements of the tests that involve visual processing points not only to the effects of the reported visual problems, but even more particularly to disturbances affecting the right hemisphere first. Nevertheless, the declines in left-hemisphere functions (especially verbal) lag only slightly behind. These findings are generally consistent with the EEG results, pointing to the right occipital as the point of attack. The rate of decline is much faster and sharper than typical in cases of progressive dementia, such as dementia of the Alzheimer's type.

DISCUSSION

There are a number of atypical features in the case reported here. In the literature on CJD, though there are several reports of aphasia as an initial presenting symptom of CJD [43], there is no previous mention of agraphia, which in JR's case appears in retrospect to have been the first explicit neurological symptom. A careful examination of Fig. 1 will reveal that JR's difficulties with writing are not simply the result of distorted vision; in this context the co-occurring perseveration and disorganization are especially revealing. Writing requires both a visual and motor image of the letters to be formed [44], and is thus somewhat more dependent on right-hemisphere functions than is speech.

It emerges rather clearly from the data and history presented above that JR is most likely suffering from one of the rarest forms of CJD, the Heidenhain variant, first described by Heidenhain in 1929 [30]. These patients typically present at an early stage with hemianopsia, but without pyramidal symptoms or lesion detectable by neuroimaging [45], followed by progressive metamorphopsia [8], visual hallucinations, and diminished visual acuity, culminating in cortical blindness without remarkable ocular pathology. Furthermore, all reported cases of

the Heidenhain variant to date have been positive for the 14-3-3 marker protein in CSF. To this point, JR's profile fits these diagnostic criteria precisely. However, decline in this variant is rapid and decrease occurs within 5-7 months of onset [8], whereas JR, after a rapid decline in December 2000 - January 2001, has survived for almost a year. The absence of either genetic or environmental factors clearly predisposing JR to CJD is also puzzling. If indeed this patient has Hv-CJD, then there are some very serious and very important questions to be asked about the course of the disease and the mode of transmission. It would be premature at this point, however, to address these issues without neuropathological results.

The evolution of hallucinations in this case is particularly interesting. The process that led in JR's case from visual disorders to hallucinations can be conceived as a series of statements:

- I see black spots on the wall.
- The black spots look like bugs.
- The black spots are bugs.
- There are black bugs climbing up the wall.

In other words, the patient began by describing the visual phenomenon, being fully aware that the spots she was seeing were not really there on the wall (which in fact prompted her to seek medical attention). Later she used an analogy to describe the appearance of these black spots, but in time the analogy lost its metaphorical force and became a statement of fact. At that point the patient lost all criticism and interpreted what she was seeing literally, using the category suggested by the metaphor. Under the influence of anxiety and dementia, producing a loss of criticism, the visual disorders were gradually transformed into psychotic disturbances.

CONCLUSIONS

1. The case here described, which exhibits all the clinical features of Creutzfeldt-Jakob Disease, is remarkable for agraphia as the first presenting symptom, the absence of obvious genetic or environmental risk factors, and the somewhat protracted course.
2. The clinical picture is largely consistent with the Heidenhain variant of CJD, except for the patient's survival for more than a year after first presentation. The symptomatology suggests that the initial point of attack for the spongiform encephalopathy was in the right occipital lobe.

3. The mode of transmission of CJD in JR's case is unclear, especially in the absence of any genetic or environmental factors known to be conducive to contracting CJD.
4. In cases of vision disturbances without ocular pathology, when other neurological causes have been ruled out, the possibility of Hv-CJD should be considered.

REFERENCES

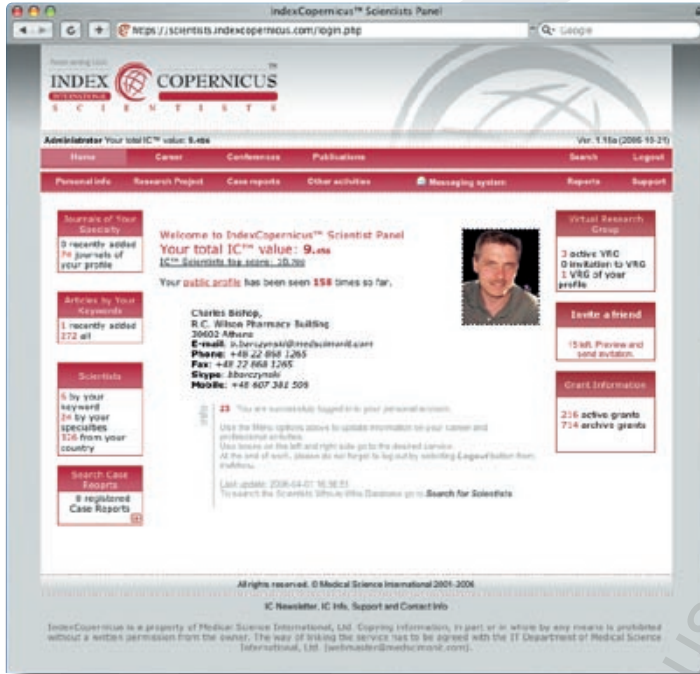1. DiMauro S: Mitochondrial encephalomyopathies. In: Rosenberg RN, Prusiner SB, DiMauro S et al: *The molecular and genetic basis of neurologic disease*. 2nd edition. Boston: Butterworth-Heinemann; 1996
2. Kretzschmar H: Nicht nur als Differenzialdiagnose der Alzheimer-Demenz interessant. BSE und andere Prionkrankheiten [Interesting not only as differential Alzheimer dementia diagnosis. Bovine spongiform encephalopathy and other prion diseases]. *MMW Fortschr Med*, 2000; 142(39): 34-8
3. Majeed A, Lehmann P, Kirby L et al: Extent of misclassification of death from Creutzfeldt-Jakob disease in England 1979-96: retrospective examination of clinical records. *BMJ*, 2000; 320(7228): 145-7
4. Mastrianni A, Roos RP: *The prion diseases*. *Seminars in Neurology*, 2000; 20(3): 337-352
5. Ogawa T, Inugami A, Fujita H et al: Serial positron emission tomography with fludeoxyglucose F18 in Creutzfeldt-Jakob disease. *Am J Neuroradiol*, 1995; 16(4 Suppl): 978-81
6. Zeidler M, Stewart GE, Barraclough CR et al: New variant Creutzfeldt-Jakob disease: neurological features and diagnostic tests. *Lancet*, 1997; 350: 903-907
7. Pachalska M, Talar J, Brodziak A, MacQueen BD: Disturbances of mental image processing in post-stroke patients with left and right hemisphere damage. *Med Sci Monit*, 2001; 7(4): 716-724
8. Kropp S, Schulz-Schaeffer WJ, Finkenstaedt M et al: The Heidenhain variant of Creutzfeldt-Jakob disease. *Arch Neurol*, 1999; 56(1): 55-61
9. Jibiki I, Fukushima T, Kobayashi K et al: Utility of 123I-IMP SPECT brain scans for the early detection of site-specific abnormalities in Creutzfeldt-Jakob disease (Heidenhain type): a case study. *Neuropsychobiology*, 1994; 29(3): 117-9
10. Grunwald F, Pohl C, Bender H, Hartmann A, Menzel C, Ruhlmann J, Keller E, Biersack HJ: 18F-fluorodeoxyglucose-PET and 99mTc-bicisate-SPECT in Creutzfeldt-Jakob disease. *Ann Nucl Med* 1996;10(1):131-4
11. Prusiner SB, McKinley MP, Groth DF et al: Scrapie agent contains a hydrophobic protein. *Proc Natl Acad Sci USA* 1981;78:6675-6679
12. Büeler H, Fischer M, Lang Y et al: Normal development and behaviour of mice lacking the neuronal cell-surface PrP protein. *Nature*, 1992; 356: 577-582
13. Oesch B, Westaway D, Wälchli M et al: A cellular gene encodes scrapie PrP 27-30 protein. *Cell*, 1985; 40: 735-746
14. Palmer MS, Mahal SP, Campbell TA et al: Deletions in the prion protein gene are not associated with CJD. *Hum Mol Genet*, 1993; 2: 541-544
15. Safar J, Roller PP, Gajdusek DC, Gibbs CJ Jr: Conformational transitions, dissociation, and unfolding of scrapie amyloid (prion) protein. *J Biol Chem*, 1993; 268: 20276-20284
16. Bessen RA, Marsh RF: Distinct PrP properties suggest the molecular basis of strain variation in transmissible mink encephalopathy. *J Virol*, 1994; 68: 7859-7868
17. Creutzfeldt HG. Über eine eigenartige herdförmige Erkrankung des Zentralnervensystems. *Z Gesamte Neurol Psychiatr* 1920;57:1-18
18. Jakob A: Über eine der multiplen Sklerose klinisch nahestehende Erkrankung des Zentralnervensystems (spastische Pseudosklerose) mit bemerkenswertem anatomischem Befunde. Mitteilung eines vierten Falles. *Med Klin*, 1921; 17: 372-376
19. Holm IE, Abelskov K, Bojsen-Moller M et al: Creutzfeldt-Jakob disease segregating in a three generation Danish family. *Acta Neurol Scand*, 2001; 103(3): 139-47
20. Kretzschmar HA, Neumann M, Stavrou D: Codon 178 mutation of the human prion protein gene in a German family (Backer family): sequencing data from 72-year-old celloidin-embedded brain tissue. *Acta Neuropathol (Berl)*, 1995; 89(1): 96-8
21. Lang CJ, Schuler P, Engelhardt A et al: Probable Creutzfeldt-Jakob disease after a cadaveric dural graft. *Eur J Epidemiol*, 1995; 11(1): 79-81
22. Scott A, De R, Sadek SA et al: Temporal bone dissection: a possible route for prion transmission? *J Laryngol Otol*, 2001; 115(5): 374-5
23. Billette de Villemeur T, Gelot A, Deslys JP et al: Iatrogenic Creutzfeldt-Jakob disease in three growth hormone recipients: a neuropathological study. *Neuropathol Appl Neurobiol*, 1994; 20: 111-117
24. Billette de Villemeur T, Beauvais P, Goumilon M, Richardet JM: Creutzfeldt-Jakob disease in children treated with growth hormone. *Lancet*, 1991; 337: 864-865
25. Brown P, Gajdusek DC, Gibbs CJ Jr, Asher DM: Potential epidemic of Creutzfeldt-Jakob disease from human growth hormone therapy. *N Engl J Med*, 1985; 313: 728-731
26. Deslys J-P, Marcé D, Dormont D: Similar genetic susceptibility in iatrogenic and sporadic Creutzfeldt-Jakob disease. *J Gen Virol*, 1994; 75: 23-27
27. Cochiu JI, Mack K, Burns RJ et al: Creutzfeldt-Jakob disease in a recipient of human pituitary-derived gonadotrophin. *Aust N Z J Med*, 1990; 20: 592-593
28. Prusiner SB: Prion diseases and the BSE crisis. *Science*, 1997; 278: 245-251
29. Rabenau HF, Preiser W, Doerr HW: Übertragbare spongiforme Encephalopathien: die Creutzfeldt-Jakob-Krankheit [Transmissible spongiform encephalopathies: Creutzfeldt-Jakob disease]. *Chirurg*, 1998; 69(5): 511-21
30. Heidenhain A: Klinische und anatomische untersuchungen uber eine eigenartige erkrankung des zentralnervensystems im praesenium [Clinical and anatomical investigations of a unique disease of the central nervous system in the praesenium]. *Z Gesamte Neurol Psychiatr*, 1929; 118: 49
31. Kitagawa Y, Gotoh F, Koto A et al: Creutzfeldt-Jakob disease: a case with extensive white matter degeneration and optic atrophy. *J Neurol*, 1983; 229: 97-101
32. Hsich G, Kenney K, Gibb C et al: The 14-3-3 brain protein in cerebrospinal fluid as a marker for transmissible spongiform encephalopathies. *New England Journal of Medicine*, 335, 924-930

33. Cataldi ML, Restivo O, Reggio E, Restivo DA, Reggio A. Deafness: an unusual onset of genetic Creutzfeldt-Jakob disease. *Neurolog Sci*, 2000; 21(1): 53-5
34. Staffen W, Trinka E, Iglseder B et al: Clinical and diagnostic findings in a patient with Creutzfeldt-Jakob disease (type Heidenhain). *J Neuroimaging*, 1997; 7(1): 50-4
35. Lee KE, Loh NK, Tan AK et al: Creutzfeldt-Jakob disease presenting with visual blurring, diplopia and visual loss: Heidenhain's variant. *Ann Acad Med Singapore*, 1998; 27(6): 854-6
36. Aharon-Peretz J, Peretz A, Hemli JA et al: SPECT diagnosis of Creutzfeldt-Jacob disease. *J Nucl Med*, 1995; 36(4): 616-7
37. Pačalska M, Kurzbauer H, MacQueen BD et al: Neuropsychological features of rapidly progressive dementia in Creutzfeldt-Jakob Disease, Heidenhain variant. *Neurologia i Neurochirurgia Polska*, 2001; Suppl. 2: 10
38. Kertesz A, Poole E: The aphasia quotient: the taxonomic approach to measurement of aphasic disability. *Canadian Journal of Neurological Sciences*, 1974; 1: 7-16
39. Kaplan E, Goodglass H, Weintraub S: *The Boston Naming Test*. Philadelphia: Lea and Febiger; 1983
40. Wechsler D: *WAIS-R manual: Wechsler Adult Intelligence Scale - Revised*. San Antonio, Texas: Psychological Corporation; 1981
41. Wechsler D: *WMS-R manual: Wechsler Memory Scale - Revised*. San Antonio, Texas: Psychological Corporation; 1986
42. Pačalska M, MacQueen BD, Knapik H: Disintegration of higher level language functions in post-stroke patients with anterior and posterior right hemisphere lesions. In: Bastianse, N, ed. *Proceedings of the 9th International Aphasia Rehabilitation Congress*. Rotterdam: Rotterdam Aphasia Foundation, 2000; 27
43. Hillis AR, Selnes O: Cases of aphasia or neglect due to Creutzfeldt-Jakob Disease. *Aphasiology*, 1999; 13(9-11): 743-754
44. Brodziak A: Neurophysiology of the mental image. *Med Sci Monit*, 2001; 7(3): 534-538
45. Brazis PW, Lee AG, Graff-Radford N et al: Homonymous visual field defects in patients without corresponding structural lesions on neuroimaging. *J Neuroophthalmol*, 2000; 20(2): 92-6

Index Copernicus

Global Scientific Information Systems for Scientists by Scientists

www.IndexCopernicus.com



TM
INDEX
COPERNICUS
INTERNATIONAL

EVALUATION & BENCHMARKING

PROFILED INFORMATION

NETWORKING & COOPERATION

VIRTUAL RESEARCH GROUPS

GRANTS

PATENTS

CLINICAL TRIALS

JOBS

STRATEGIC & FINANCIAL DECISIONS

Index Copernicus integrates

IC Journal Master List

Scientific literature database, including abstracts, full text, and journal ranking. Instructions for authors available from selected journals.

IC Conferences

Effective search tool for worldwide medical conferences and local meetings.

IC Scientists

Effective search tool for collaborators worldwide. Provides easy global networking for scientists. C.V.'s and dossiers on selected scientists available. Increase your professional visibility.

IC Patents

Provides information on patent registration process, patent offices and other legal issues. Provides links to companies that may want to license or purchase a patent.

IC Grant Awareness

Need grant assistance? Step-by-step information on how to apply for a grant. Provides a list of grant institutions and their requirements.

IC Virtual Research Groups [VRG]

Web-based complete research environment which enables researchers to work on one project from distant locations. VRG provides:

- ① customizable and individually self-tailored electronic research protocols and data capture tools,
- ① statistical analysis and report creation tools,
- ① profiled information on literature, publications, grants and patents related to the research project,
- ① administration tools.

IC Lab & Clinical Trial Register

Provides list of on-going laboratory or clinical trials, including research summaries and calls for co-investigators.