

A Single Case Study of Diabetic Ulcer with Charcot's Deformity

Dr. P. V. Vijay Guptha¹, Dr. Syeda Ather Fathima², Dr. Shivalingappa J. Arakeri³,
Dr. Mohasin Kadegaon⁴, Dr. Geethanjali Hiremath⁵

¹PG Scholar, ²Principal, ³Professor & HOD, ⁴Assistant Professor, ⁵Assistant Professor,
^{1,3,4,5}Department of Shalya Tantra, Taranath Government Ayurvedic Medical College, Ballari, Karnataka, India
²Taranath Government Ayurvedic Medical College, Ballari, Karnataka, India

ABSTRACT

In patients with diabetes the incidence of acute charcot arthropathy of the foot and ankle ranges from 0.15-2.5%. It occurs as a result of arthritis in joint in diabetic patients. In contemporary science the management of wound is by oral and topical antibiotics along with use of betadine solution and eusol are in practice for wound care. Gomutra Arka been widely practiced for Vranshodhana and most of the time it is not accepted by group of people, because of smell and religious factor. So, there is a need for alternate simple and effective formulation which can be used in all wound for Vranashodhana. Hence here is an effort to find better substitute for the wound care and healing. A male patient 62 years old visited OPD Taranath Government Ayurvedic Medical College with complaint of Wound in right foot 3rd toe tip and got diagnosed as T2DM/HTN/Diabetic Ulcer with Charcot's Deformity. Successfully treated the wound with Karanja Arka Prakshalana for wound care. Few internal medication and Pathya Apathya for 21 days.

Keywords: Charcot's arthropathy, Prakshalana, Pathya Apathya

1. INTRODUCTION

The diabetic Charcot foot syndrome is a serious and potentially limb-threatening lower-extremity complication of diabetes. First described in 1883, this enigmatic condition continues to challenge even the most experienced practitioners. Now considered an inflammatory syndrome, the diabetic Charcot foot is characterized by varying degrees of bone and joint disorganization secondary to underlying neuropathy, trauma, and perturbations of bone metabolism. The Charcot foot in diabetes poses many clinical challenges in its diagnosis and management. Despite the time that has passed since the first publication on pedal osteoarthropathy in 1883, there is much to learn about the pathophysiology, and little evidence exists on treatments of this disorder. Charcot neuropathic osteoarthropathy (CN), commonly referred to as the Charcot foot, is a condition affecting the bones, joints, and soft tissues of the foot and ankle, characterized by inflammation in the earliest phase. The hallmark deformity associated with this condition

is midfoot collapse, described as a "rocker-bottom" foot although the Charcot syndrome may occur in a variety of conditions; diabetes is clearly the most common worldwide. Diabetes may predispose to its occurrence through a number of mechanisms. Apart from the presence of neuropathy and possible osteopenia, these include the effects of advanced glycation end products, reactive oxygen species, and oxidized lipids, which may all enhance the expression of RANKL¹ (Receptor activator of nuclear factor kappa-B ligand) in diabetes. Treatment² in its early stage is towards reducing swelling and heat in the area, stabilizing the foot by keeping it immobile. Non-surgical (wearing a protective splint, walking brace, off-loading etc.) and surgical treatments (reconstructive osteotomy, ankle fusion, exostectomy and amputation and prosthetic fitting).

CASE REPORT

A 62 year old male patient visited to out-patient department (OPD) at Taranath Government

How to cite this paper: Dr. P. V. Vijay Guptha | Dr. Syeda Ather Fathima | Dr. Shivalingappa J. Arakeri | Dr. Mohasin Kadegaon | Dr. Geethanjali Hiremath "A Single Case Study of Diabetic Ulcer with Charcot's Deformity" Published in International Journal of Trend in Scientific Research and Development (ijtsrd), ISSN: 2456-6470, Volume-5 | Issue-6, October 2021, pp.1287-1291,
www.ijtsrd.com/papers/ijtsrd47631.pdf



URL:

Copyright © 2021 by author (s) and International Journal of Trend in Scientific Research and Development Journal. This is an Open Access article distributed under the terms of the Creative Commons Attribution License (CC BY 4.0) (<http://creativecommons.org/licenses/by/4.0>)



Ayurvedic Medical College, Ballari, Karnataka on 11/08/2021 presented with complaints of wound, pain in right foot 3rd toe tip since 6 months.

History of Present Illness: Patient was said to be apparently alright 10 years back. Then he had nail injury to right foot. Which caused pain and swelling in anterior 1/3rd of foot with swelling extending upto ankle. He operated for the same from VIMS, Ballari. Then he underwent 5th toe right foot amputation. Recently he developed ulcer in 3rd toe tip region along with pain and swelling. Visited Taranath Government Ayurvedic Medical College, Ballari for the same.

History of Past History: K/C/O type 2 DM (14years)/HTN (6years)

Drug History:

1. Tab. Glycomet GP1 morning A/F
2. Tab. Glycomet 500 night A/F
3. Tab. Atenolol 50 BID A/F

4. Systemic examination:

CVS: S1S2 heard, no any added sounds
RS: normal vesicular breath sounds
P/A: soft, normal bowel sounds, no organomegaly

Local Examination:

Inspection

Site: 3rd right foot toe tip
Size: 2cm * 1.5cm
Shape: oval
Edge: sloping
Floor: pale granulation with unhealthy tissue seen
Discharge: mild serous
Surrounding area: blackish pigmentation with callosity
Margin: regular

Diagnosis: T2DM/HTN/DIABETIC ULCER with Charcot's Deformity

Treatment Adopted:

Days 1 to 21

Karanja Arka Prakshalana followed by dressing.

Internally

1. Kaishora Guggulu 1 TDS
2. Kokilaksha Kashayam 10ml TDS Before Food

Strict Pathya Apathya as advised.

Personal History:

- Appetite: poor
- Diet: mixed
- Bowel: Regular
- Sleep: Disturbed due to pain
- Micturition: 4-5 times/ day
2-3 times/ night

Habits: occasional alcohol intake, Smoking present

Occupational History: X-Servicemen, Farmer

Examination:

1. Built: moderate
2. Vitals were normal

3. General examination:

Pallor- Absent	Cyanosis- Absent
Icterus- Absent	Lymphadenopathy- Absent
Clubbing- Absent	Edema- pitting edema + (Right Leg and Foot)

Smell: absent

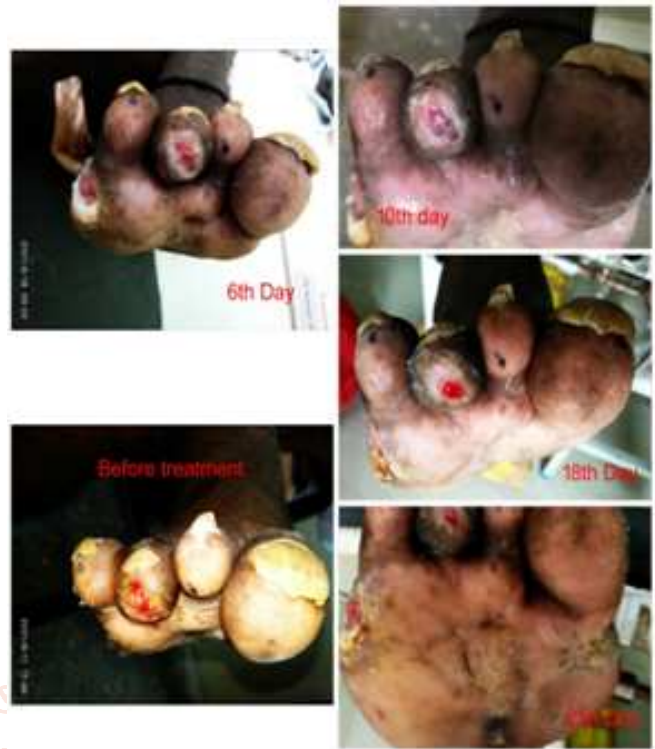
Palpation

Tenderness: absent
Swelling: present in right leg and foot, pitting
Induration: Absent
Temperature: Absent
Pulsation:
Dorsalis pedis- good
Posterior tibial- feeble
Anterior tibial- good

Fig: 01

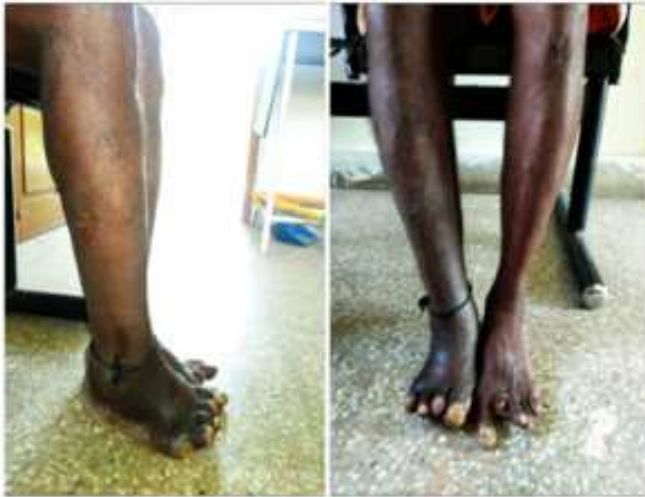
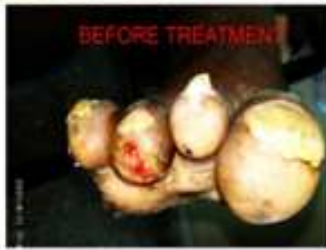
Fig: 02



Before Treatment

during and After Treatment

Fig: 03

Fig: 04

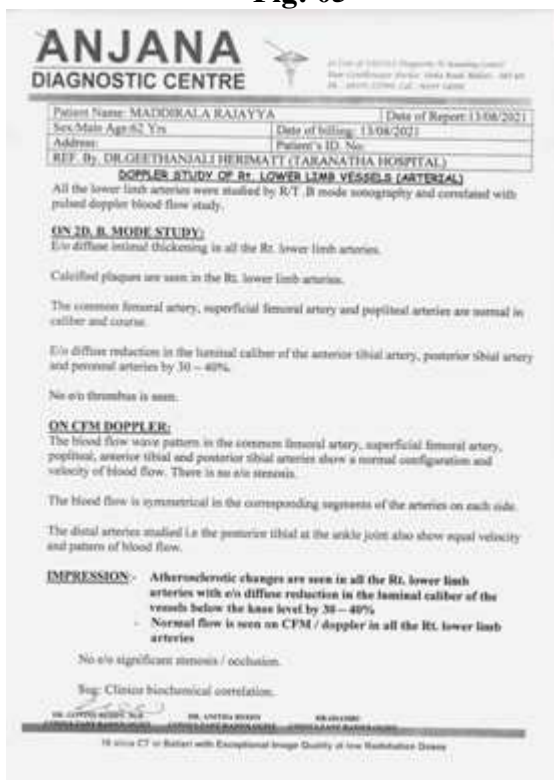
A M R U T H DIAGNOSTIC LABORATORY		Tel : 08392 - 256106	
1st Cross, Gandhi Nagar, BALLARI-583103. (Karnataka State)			
Name : Sri Rajayya	Date : 21/08/2021	Page 1 of 1	
Age : 62 Years	Sex : Male	Ref. by : Dr.Shivalingappa	
Parameters	Results	Reference Range	
BIO-CHEMISTRY			
RBS	221.2 mg/dl	70 - 140	
HBA1C	9.7 %	+ 6 (Near diabetic) 6 - 7 (Near normal glycaemia) + 7 (Good) 7 - 9 (Good Control) + 9 (Action suggested)	
Estimated average glucose HPLC- BORAD D 10	231.7 mg/dl		
UREA	10.5 mg/dl	< 40.0	
S. CREATININE	0.8 mg/dl	M.O.S - 1.4 F. O.S - 1.4	
SEROLOGY			
CMP (Nephelometry Method)	1.2 mg/dl	up to 6.0	
— End of Report —			
Ref. No. : 331		Dr. P. Sreedhara Murthy, M.B.B.S., DCP Pathologist	
		Pathologist Dr. P. Sreedhara Murthy M.B.B.S., DCP	

Blood Investigation

GOVERNMENT OF KARNATAKA		
TARANATH GOVT. AYURVEDIC MEDICAL COLLEGE & HOSPITAL, BELLARY - 583 101.		
Laboratory		
Patient Name : SAGITHA - 62 / 46		Reported : 20/08/2021 10:03 AM
Ref. By Dr. : DR. SHIVALINGAPPA		Sample Received : 20/08/2021 - 02 AM
SPD : DR. SHIVALINGAPPA		LAB No. : 2127/2021
TESTS	RESULTS	NORMAL VALUES
BIO-CHEMISTRY		
FASTING BLOOD SUGAR (FBS)	180 mg/dl	70 - 110 mg/dl
POST PRANDIAL BLOOD SUGAR (PPBS)	270 mg/dl	80 - 140 mg/dl
HEMATOLOGY		
Hb%	12.5 g/dl	14.0 - 18.0 g/dl
E.S.R	27 mm/1 hour	30 - 50 mm/1 hour
BLEEDING TIME	2 MIN:50 SEC	1 - 4 MIN:00 SEC
CLOTTING TIME	3 MIN:00 SEC	1 - 2 MIN:00 SEC
SEROLOGY		
HIV 1 & 2	NEGATIVE	
Hbs Ag	NEGATIVE	
Dr. P. Sreedhara Murthy Pathologist		

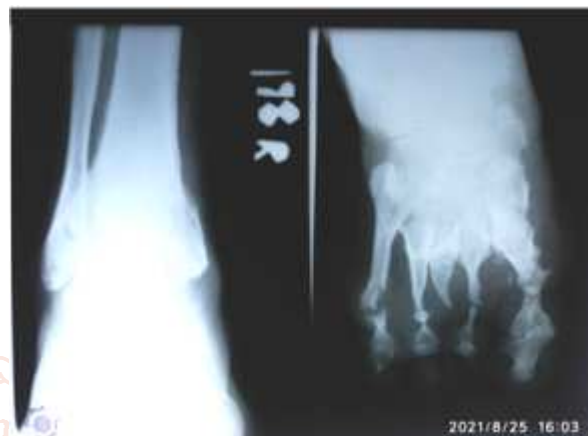Blood Investigation

Fig: 05



Arterial Doppler

Fig: 06



X- Ray foot

Table No. 01: Findings of Ulcer Before and After Treatment

Symptom	BT	7 th Day	14 th Day	21 st Day
1.Pain	Present	Present	Reduced	No pain
2.Itching	Absent	Absent	Absent	Absent
3.Foul smell	Absent	Absent	Absent	Absent
4.Size	2cm*1.5cm	1.5cm*1cm	1cm*0.5cm	Healed
5.Edge	Sloping	Sloping	Sloping	Sloping
6.Margin	Regular	Regular	Regular	Regular
7.Floor	Slough with beafy granulation tissue	Beafy granulation tissue	Pinkish granulation tissue	Healed
8.Discharge	Mild sero-purulent	Mild serous	Serous	Absent

DISCUSSION

The prevalence of Charcot’s arthropathy ranges from 0.1% to as high as 13% in specialized foot clinics. In patients with diabetes the incidence of acute charcot arthropathy of the foot and ankle ranges from 0.15-2.5%. Epidemiological studies do not distinguish between acute and post acute disease. The 62 year old male patient approached our hospital with complaints of wound in right foot 3rd toe tip with charcot deformity. Got successfully treated for the wound.

PROBABLE MODE OF ACTION:

- He was treated with karanja arka³ for vrana prakshalana which has vrana shodhana and ropana action.
- Kaishora guggulu has rakta gata dosha pachana, rakta prasadana and medo hara action, which helped in managing the diabetic ulcer

microcirculation and atherosclerotic changes in arteries.

Kokilaksha kashayam is a know formulation in the management of Vatarakta. Which is used to treat Gout and many types of arthritis.

The charcot’s deformity is a result of arthritis of joint occurring in diabetic patient. So, the combination of kaishora guggulu and kokilaksha kahshayam been used to manage the condition.

CONCLUSION:

Diabetic ulcer with charcot deformity is rare presentation and often the diagnosis is missed. This patient was having atherosclerotic changes in lower limb arteries, T2DM, HTN which was interfering with wound healing. He was diagnosed with diabetic ulcer with charcots deformity and was treated the wound successfully with Ayurvedic medicine like

internally Kaishora Guggulu and Kokilaksha Kashayam. Externally, Karnja Arka Prakshalana followed by dressing to manage wound. As it was single case study it needs further evaluation and efficacy of the drug and procedure.

BIBLIOGRAPHY

[1] Boyce BF, Xing L. Functions of RANKL/RANK/OPG in bone modeling and

remodeling. Arch Biochem Biophys 2008; 473: 139-146

[2] <https://www.healthline.com/health/charcot-foot>

[3] Tripathi Indradeva, Arka prakasha of Lankapathy Ravana. 2nd ed. Varanasi: Chowkhamba Krishnadas Academy; 2006.

