

Fluoroscopy Guided Lumbar Facet Joint Block as a Diagnostic Tool in the Evaluation of Chronic Low Back Ache

Khaja Javed Khan¹, Satish Kumar M N², Wiquar Ahmed³, Prashanth R Putran⁴

How to cite this article:

Khaja Javed Khan, Satish Kumar M N, Wiquar Ahmed, et.al. / Fluoroscopy Guided Lumbar Facet Joint Block as a Diagnostic Tool in the Evaluation of Chronic Low Back Ache/Indian J Anesth Analg. 2022;9(6)301-303.

Abstract

Acute low back pain is a common cause of pain in majority of adult population. Facet joints are potential source of pain in low back pain (LBP) and its prevalence increases with age. Our case report is about a 34 year old male patient came with chief complaints of chronic low back ache, more on the left side, insidious in onset, non radiating not associated with tingling or numbness. Pain aggravates on walking, sitting to standing posture and left side movements. His Numerical rating scale (NRS) was 7 and Verbal rating scale (VRS) was moderate. On palpation patient had left para median tenderness more at L5-S1 area. The Lasague straight leg raising test and flexion, abduction, external rotation (FABER) were also negative. We decided to proceed with diagnostic block of left L5-S1 facet joint with 1ml of 1% lignocaine and our patient had significant pain relief of about 80%.

Keywords: Low Back Pain; Facet Joint; Diagnostic block.

INTRODUCTION

Acute low back pain is a common cause of disability in both young and middle-aged individuals and is prevalent in 4-33% of the population. Facet joint pain contributes to a significant proportion of this prevalence.¹ The lumbar facet joints are innervated by the medial

branch of the dorsal ramus of the nerve exiting at the same level and the medial branch of the nerve one level above. The innervation of L5-S1 facet joint differs from the other lumbar joints since it is innervated by the medial branch of L4 and the dorsal ramus of L5.² Lumbar facet joints (FJs) constitute a common source of pain and remain a misunderstood, misdiagnosed and improperly treated pathology.³ Clinical facet joint syndrome is defined as a unilateral or bilateral back pain radiating to one or both buttocks, sides of the groin, and thighs, and stopping above the knee. However, in some cases, patient symptoms in the setting of low back pain may lack specificity, as facet joints may mimic the pain caused by herniated discs or compressed roots. History and clinical examination may suggest, but not confirm FJs as the source of pain. A positive diagnostic facet joint block usually

Author's Affiliation: ^{1,3,4}Consultant, ²Resident, Department of Pain Medicine, Alleviate Pain Hospital, Bengaluru 560057, Karnataka, India.

Corresponding Author: Satish Kumar M N, Resident, Department of Pain Medicine, Alleviate Pain Hospital, Bengaluru 560057, Karnataka, India.

E-mail: drsats007@gmail.com

Received on: 18.07.2022

Accepted on: 22.09.2022

confirms facet joints as the source of chronic back pain.⁴

CASE HISTORY

A 34 year old male patient software engineer by occupation came to our outpatient department with chief complaints of low back ache since 3 and half months more on the left side. Pain was insidious in onset, non radiating, moderate dull aching and not associated with tingling or numbness. Pain aggravated on walking, sitting to standing posture and got relieved on rest. On pain assessment scale his Numerical rating scale (NRS) was 7 and Verbal rating scale (VRS) was moderate. No H/O of accident, injury, other joint pain. Patient had taken a course of NSAIDs along with muscle relaxants and physiotherapy but there was no improvement in his pain.

On Examination, during inspection gait, spine curvature and contour of the muscles on either sides appeared to be normal. On palpation patient had left para median tenderness more at L5-S1 area, no localised rise of temperature, no sensory and motor deficit, all reflexes were intact. Patient complained of pain on left lateral bending and left side rotation. The Lasegue straight leg raising test was negative and flexion abduction external rotation (FABER), flexion adduction internal rotation (FAIR) tests, Sacroiliac joint tenderness were also negative.

We thought of differential diagnosis of left side facet joint arthropathy and myofascial pain syndrome. Hence we decided to proceed with diagnostic block of left L5-S1 facet joint.

After taking written informed consent patient was shifted to operation theatre, painted and draped. Under strict aseptic precautions under fluoroscopy guidance left L5-S1 facet joint was identified as most tender point on palpation.(Fig. 1)

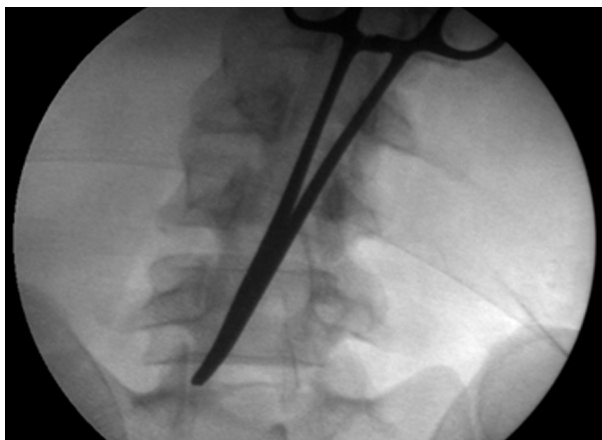


Fig. 1: Pointer placed at Left L5-S1 facet joint.

and hence we decided to do left L5-S1 facet intra-articular injection using 22g spinal needle (Fig. 2).

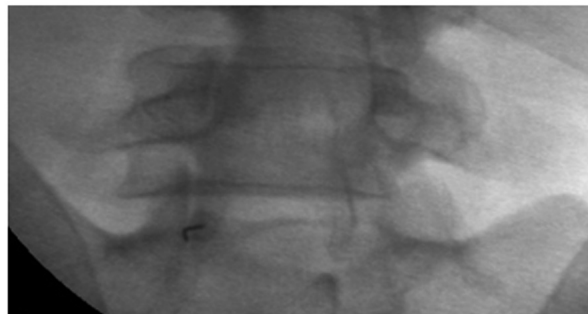


Fig. 2: 22g spinal needle placed at Left L5-S1 intraarticular area.

Intra-articular facet joint block was given with 1ml of 1% lignocaine after confirming negative aspiration. After the procedure patient was monitored for vitals and pain assessment. There was a significant improvement in pain score for NRS from 7 to 2 and VRS moderate to mild after 30 minutes of procedure. Patient had significant pain relief of about 80%.

DISCUSSION

In 1980, Bogduk and Long demonstrated that pain in the back and thigh could be produced by injecting 6% hypertonic saline solution in the regions of the medial branch. Medial branches of the dorsal ramus of the spinal nerve are distributed on the external periosteum, facet joints, and ligamentous connections of the neural arches and the sinuvertebral nerve. Low back pain may originate from the external periosteum, facet joints, muscle, and the ligamentous connection of the neural arches.⁵

In our case the patient had chronic low back pain at left lower facet joint area with all the clinical tests were not in favour of facet joint and sacroiliac joint involvement. Myofascial pain syndrome was one of the differential diagnosis in our case but confirmation was yet to be made. Hence we decided diagnostic block for left side intraarticular (IA) facet joint block at L5-S1 levels with 1ml of 1% lignocaine.

In a retrospective study by Helbig and Lee performed in 22 patients, the authors sought to correlate response to an IA facet injection with diagnostic criteria that included pain in the back, buttock, leg or groin, signs of spasms or deformity, paravertebral tenderness, pain with motion and neurological examination. Back pain radiating to the groin or leg, pain worsened with extension-rotation and well-localized paraspinous tenderness were associated with a positive outcome, which

was defined as prolonged relief lasting >6 months. Pain radiating below the knee was negatively associated with a positive response to facet blocks.⁶

Seo JH et al. compared the efficacy of combined treatment with medial branch block and facet joint injection in axial low back pain and concluded that combined treatment can reduce axial low back pain and improve secondary functional degradation, but it required longer intervention time and did not have pain relief effect superior to that of medial branch block and facet joint injection alone.⁷

Facet joint disturbances can be responsible for 10% to 50% of all cases of chronic lumbar pain.⁸⁻¹¹ However, clinical history or physical examination cannot identify facet joint alterations as the origin of pain, nor does imaging. The only tool to identify facet joint alterations as the cause of pain is the verification of an analgesic response to anesthetic injections into the facet joints or at their nerve supplies and medial dorsal branch blocks are easier to perform. A positive result (i.e., pain relief) would mean that the facet joint is the site from which the pain originates.¹²

CONCLUSION

This case report describes the management of patient with low back ache with diagnostic block at L5-S1 facet joint when all other treatment options were not producing pain relief. Subsequently this patient can be treated with therapeutic lumbar facet joint intervention if pain recurs.

REFERENCES

1. Rajesh MB, Chamma R, Ranganathan A. Management Strategies in Chronic Lumbar Facet Joint Syndrome - A Review of Literature. *J Musculoskelet Disord Treat*. 2019; 5(3):068 DOI: 10.23937/2572-3243.1510068.
2. Masini M, Paiva WS, Araújo AS Jr. Anatomical description of the facet joint innervation and its implication in the treatment of recurrent back pain. *J Neurosurg Sci*. 2005;49(4):143-146.
3. Jadon A. Low Back Pain due to Lumbar Facet Joint Arthropathy and its Management. *General Medicine: Open access*. 2016; 4(3):1-5.
4. Perolat R, Kastler A, Nicot B, et al. Facet joint syndrome: from diagnosis to interventional management. *Insights Imaging*. 2018; 9(5): 773-789.
5. KT Kim, SW Park, YB Kim et al. The Effect of Lumbar Medial Branch Block on Low Back Pain. *J Korean Neurosurg Soc*. 2006; 40 : 256-261.
6. Helbig T, Lee CK. The lumbar facet syndrome. *Spine* 1988;13:61-4.doi :10.1097/00007632-198801000-00015.
7. Seo JH, Baik SW, Ko MH et al. Comparing the efficacy of combined treatment with medial branch block and facet joint injection in axial low back pain. *Pain Res Manag*. 2021:1-6 DOI:10.1155/2021/1343891.
8. Schwarzer AC, Aprill CN, Derby R, Fortin J, Kine G, Bogduk N. The relative contributions of the disc and zygapophyseal joint in chronic low back pain. *Spine (Phila Pa 1976)*. 1994;19(7):801-6, <http://dx.doi.org/10.1097/00007632-199404000-00013>.
9. Manchikanti L, Boswell MV, Singh V, Pampati V, Damron KS, Beyer CD. Prevalence of facet joint pain in chronic spinal pain of cervical, thoracic, and lumbar regions. *BMC Musculoskelet Disord*. 2004;5:15, <http://dx.doi.org/10.1186/1471-2474-5-15>.
10. Cohen SP, Raja SN. Pathogenesis, diagnosis, and treatment of lumbar zygapophysial (facet) joint pain. *Anesthesiology*. 2007;106(3):591-614, <http://dx.doi.org/10.1097/0000542-200703000-00024>.
11. Freburger JK, Holmes GM, Agans RP, Jackman AM, Darter JD, Wallace AS, et al. The rising prevalence of chronic low back pain. *Arch Intern Med*. 2009; 169(3):251-8, <http://dx.doi.org/10.1001/archinternmed.2008.543>.
12. Rocha ID, Cristante AF, Marcon RM, Oliveira RP, Letaif OB, Barros Filho TE. Controlled medial branch anesthetic block in the diagnosis of chronic lumbar facet joint pain: the value of a three-month follow-up. *Clinics*. 2014;69(8):529-534.

