

Implant-Supported Overdenture: A Review

ABSTRACT

Complete edentulism affects adversely the overall health-related quality of life. There are many prosthetic options to rehabilitate such cases like conventional complete dentures, implant-supported overdentures and implant-supported fixed prosthesis. Choice of implant-supported overdentures for the rehabilitation of completely edentulous maxilla and mandible has many advantages over other prosthetic options in respect of reduced cost, increased retention and esthetics, maintenance ease, reduced anterior ridge resorption, limited lateral movements and hence reduced soft tissue trauma. Greater stability of overdenture is due to mechanical attachments of the implant support system retaining the restoration. Various attachment systems are currently available to restore implant-supported overdenture and are used according to the clinical case scenario.

KEYWORDS implant-supported overdenture, ridge atrophy, overdenture attachments

INTRODUCTION

Edentulism is a problem that affects millions of people worldwide. Tooth lost due to trauma, caries, periodontal disease, congenital defects or iatrogenic causes, is multifactorial which, if left unresolved, may progress to complete edentulism¹. The sequelae of tooth loss are reduced self-confidence, taboo and the feeling of premature ageing, alveolar bone resorption, affected nutrition². Adult dental health survey in the UK³, the US found that edentulous people had a lower daily intake of protein, fibre, calcium, iron and vitamin C, and more cholesterol, saturated fat. Intake of fibrous and nutritious food is higher for those with implant-supported overdentures⁴. In the past, conventional dentures have been the primary treatment choice for the rehabilitation of completely edentulous arches, but patients usually report problems with conventional dentures is retention and stability particularly in the mandible⁵. For many years, traditional complete denture designs have been modified to gain additional support and stability³. Although the majority of patients are satisfied with this treatment, many have difficulty adjusting to wearing dentures and discomfort because of an impaired load-bearing capacity. So several different strategies have been introduced to overcome the problem, and one of which is use of dental implant^{2,4,6}.

Tallegren reported that a mean decrease in anterior mandibular ridge height was four times greater than that of the maxilla. Alveolar bone loss can be reduced by provision of implants. Studies have shown that implant-supported mandibular over dentures can preserve bone height². Patients with implant overdentures had higher satisfaction scores and efficiency^{7,8}. Numerous clinical prospective studies up to 12 years have proven that two mandibular intraforaminal implants, splinted or unsplinted, retaining an overdenture provide successful treatment for edentulous mandibles⁹⁻¹¹.

HISTORY

During the early period, the Branemark group considered prosthodontic treatment associated with fixed implant-supported prostheses, which provides great benefits of oral function and quality of life. Less costly alternatives were needed so other prosthodontic alternatives were introduced and tested. Branemark placed the first osseointegrated implants in a human patient in 1965, and the feasibility of implant-supported overdentures was first tested at the University of Toronto in the early 1980s as a provisionalization procedure⁶. Implant-supported overdentures were described in 1985 in the first textbook on "Tissue-integrated Implants"¹². The treatment modality has

ISSN No	2230-7885
CODEN	JPB SCT
NLM Title	J Pharm Biomed Sci
DOI	https://doi.org/10.20936/jpbms/170705

Swati Sharma^{1*},
Monika Makkar¹,
Samarjit Singh Teja¹,
Preetinder Singh²

¹Department of Prosthodontics, Crown & Bridge & Oral Implantology, Swami Devi Dyal Hospital and Dental College, Barwala, Haryana, India

²Department of Periodontology & Oral Implantology, Swami Devi Dyal Hospital and Dental College, Barwala, Haryana, India

■ Address reprint requests to:

*Dr Swati Sharma, Department of Prosthodontics, Crown & Bridge & Oral Implantology, Swami Devi Dyal Hospital and Dental College, Barwala, Haryana, India
E-mail: swatisharma11dr@gmail.com

■ Article citation: Sharma S, Makkar M, Teja SS, Singh P. Implant-supported overdenture: a review. *J Pharm Biomed Sci* 2017;07(7):270-277.
Available at www.jpjpbms.info

Statement of originality of work: The manuscript has been read and approved by all the authors, the requirements for authorship have been met, and that each author believes that the manuscript represents honest and original work.

Source of funding: None.

Competing interest/Conflict of interest: The authors have no financial conflicts of interest.

Disclaimer: Any views expressed in this paper are those of the authors and do not reflect the official policy or position of the Department of Defense.

been investigated widely during the past few years, and reviews of the growing literature confirm that implant overdentures are a successful prosthetic treatment^{9,13,14}. In recent years, various attachment systems have been successfully used with removable implant overdentures. All available attachment systems are designed to intercept the vertical movement of the denture and used as a standalone attachment mounted directly to the implant or attached to a bar system¹. Ball attachments and bar units have evolved from the early 1960s. Ball attachments were the simplest type of attachments for clinical application with tooth/implant-supported overdentures. The locator attachment (Zest Anchors, Inc., homepage, Escondido, CA, USA), which initiated in 2001, is a new system, which does not use the splinting of implants. This extension is self-aligning and has dual retention with different colors and retention values¹.

Definition of an overdenture

According to GPT-9, an implant-supported overdenture is defined as a removable dental prosthesis, which are supported and retained in part or whole by dental implant¹⁵.

Advantages

Good stability, retention, support, psychological benefits, reduced residual ridge resorption and improvement in function, nutrition⁴, soft-tissue abrasions, occlusal load directions² (redirect forces more longitudinally), occlusion (reproducible centric relation occlusion)⁴, speech, comfort, tooth positions, masticatory efficiency³, hygiene conditions and home maintenance¹⁶. It is also possible to incorporate the existing denture into the new prosthesis, reduced prosthesis movements, improved, tactile discrimination¹⁷, a greater biting force, minimum anterior bone loss, reduced prosthesis size (eliminates palate flanges)², enhanced esthetics (by incorporating labial flanges for soft tissue support)^{18–20}. Bar retained over dentures showed successful results in patients underwent mandibulectomy²¹. Cost effective can be removed at night to reduce the effects of nocturnal parafunction, stress relief by sharing of occlusal load¹⁶, fewer implants are required. Abutments do not require a specific location of placement, may be extended over the abutments to prevent food entrapment.

Disadvantages

Higher financial cost^{3,22} does not satisfy physiological need of the patient. It requires proper plaque control and dental hygiene. Bulkier²³, the lack of interarch space makes an overdenture system more difficult to fabricate²⁴, loss of implants without signs of infection²⁵, problems with attachments are like dislodgement, worn, loose matrix or its respective housings²⁶.

Indications

Severe morphologic compromise of denture-supporting areas leading to lack of retention, stability and support of prosthesis, poor oral muscular coordination, low tolerance of mucosal tissues, parafunctional habits leading to recurrent soreness and instability of prosthesis, unrealistic prosthodontic expectations, active or hyperactive gag reflexes²⁷ (roofless maxillary denture), psychological inability to wear a removable prosthesis, patients who wish to improve their ability to masticate food.

Contraindications

Absolute

Uncontrolled diabetes, osteoporosis, patients undergone radiotherapy, xerostomia, psychological problems like schizophrenia, dysmorphophobia², bleeding and clotting disorders, haemophilia.

Relative

Patients who have chemical dependency of drugs like phenytoin, bisphosphonates which reduce or suppress osteoclast function and can therefore be used in the treatment of various disorders causing abnormal bone resorption. Intravenous bisphosphonate therapy is a major risk for jaw necrosis (osteonecrosis/bisphosphonate-related osteonecrosis of the jaw (BRONJ)). Oral lichen planus is a common T-cell-mediated autoimmune disease that affects stratified squamous epithelium, which alter the capacity of the oral epithelium to adhere to the titanium surface²⁸.

PATIENT ASSESSMENT AND EXAMINATION

Medical history

General wellbeing, bacterial endocarditis, hepatitis, AIDS, strokes, Clopidogrel (Plavix), warfarin (Coumadin) and aspirin (have a effect on homeostasis after surgery). Steroids and corticosteroids like prednisone, dexamethasone, and betamethasone (affect the ability to withstand stress of surgery), uncontrolled hypertension (can result in cardiovascular accident).

Dental history

Edentulous areas, contours of the edentulous ridges and tongue, facial symmetry, lip support, swellings or change in colour of the soft tissues, size and colour of the tongue, the vertical and buccolingual space available for denture construction, temporomandibular joints. Radiographically assess the anatomical landmarks, any pathology, gross anatomy of the jaws and opposing landmarks, position of mental nerve, the path of the mandibular nerve canal, width of the bone in the mandibular

symphysis area (can be measured with a pair of dividers). A revised plan of action might be emergency care, disease control, extraction of impacted teeth, transitional partial dentures, periodontal surgery, and recontouring of denture bearing areas. Previous Photographs can help in arrangement of the teeth. Available bone quantity, width, shape & length of bone, evaluation of ridge for ideal number and position of implants, abutment and attachment selection²⁹. In patients, the sulci should be examined for displaceability, width and depth. The position of the coronoid process (because it sometimes occludes the pterygomaxillary fossa in lateral movements of the mandible), ulceration, sinuses. The existing denture is examined for extension, occluding vertical relationship, occlusal plane, anterior and posterior tooth position, how the teeth meet and slide over each other, shape, color and contour of the denture teeth and denture base material.

Diagnostic workup for implant overdenture

Accurately mounted study casts in centric relation facilitate analysis of the occlusion, deflective contacts, tooth positions and angulations, jaw relationships, contours of the denture bearing areas, space available for dentures, to select a suitable path of insertion, determine undercuts relative to the pathway, plan the arrangement of artificial teeth, fabrication of the surgical guide, to choose the proper length and diameter for the implant system, the number and location of the implants, visualizes the relationship of the denture teeth, idea of the position and final design of the bar in a high smile line patient. If class II or class III or if excessive inter-ridge space is present, implant-supported overdentures are preferred over fixed bridges supported by implants.

Mandibular implant site selection

The greatest available height and optimal bone density is located in the anterior mandible, between the mental foramens (Fig. 1). Overdentures with posterior movement (RP-5) gain better acceptance than removable restorations with anterior movement. This rocking action applies torque to the abutments and increases stresses on the overdenture components and bone-implant interface. Hence, anterior forces should be resisted by implants or bars, whereas posterior forces may be directed on soft tissue area such as the buccal shelf³⁰.

Mandibular overdenture treatment options

Overdenture option 1/(OD-1)

When cost is the significant patient factor, two implants are inserted in the B and D positions and are not connected with a superstructure, bone volume should be abundant (Division A or B). The posterior ridge form should be good to excellent.

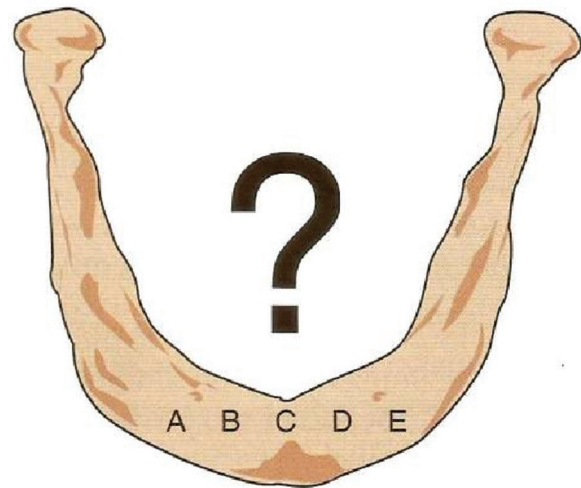


Fig. 1 Mandibular implant selection site

OD-2

Two implants are positioned in locations B and D and splinted together with a superstructure without any distal cantilever. The attachments are positioned at an equal distance off the midline, parallel to each other, at the same occlusal height, and in a similar angulation to provide added retention.

OD-3

Three implants are placed in A, C, and E position. A superstructure bar connects the implants but without distal cantilever, splinting provides a six-fold reduction in superstructure flexure, screw loosening, implant reaction forces, better distribution of forces. The implants splinted should not form a straight line. The greater the A-P spread, the greater the biomechanical advantage.

OD-4

Four implants are placed in the A, B, D, and E positions. It provides sufficient support to include a distal cantilever up to 10 mm on each side if stress factors are low, advantages like increase in implant support.

OD-5

Five implants are inserted in the A, B, C, D, and E positions. The superstructure is cantilevered distally a maximum of 2.5 times the A-P spread and averages 15 mm, which places it under the first molar area.

Arch forms

The mandibular arch form may be square, tapering, or ovoid. Square arch forms limit the A-P spread between implants and may not be able to counter the effect of a distal cantilever. Therefore rarely are distal cantilevers

designed for such arch forms. In a tapering arch form, the A-P spread is greater and therefore permits a longer distal cantilever. In an ovoid arch, the A-P spread is slightly less than tapering form. The A-P spread is only one factor to determine the length of the cantilever.

Maxillary implant overdenture treatment options

Only two treatment options are available for the maxillary implant overdentures due to poor bone quality and force direction and for the same reason, unsplinted implants and cantilever bars usually are not recommended. Option-1 has 4 to 6 implants, of which at least three are positioned in the premaxilla. Positions are: bilateral canine regions, when possible at least one central incisor position, other secondary implants may be placed in the first premolar region. In option 2, 7 to 10 implants support an RP-4 restoration. Positions are: bilateral canines, distal half of first molar, additional posterior implants are located bilaterally in the second premolar positions, in addition at least one anterior implant between the canines often is required.

Surgical procedures

The first implant placed is often used as a reference to parallel subsequent implants in an overdenture case. If the first implant is not perpendicular to the path of denture insertion, then subsequent implants will also be misaligned, compromising the placement and function. Surgical stents should be used for correct placement of implants. The attachment design dictates the implant positioning. In the case of a bar overdenture, a minimum of 18–20 mm is required to permit adequate space for the bar and sleeve attachment. When post-healing criteria for successful integration of the implant with surrounding tissues occurs with no subjective symptoms, the procedure is further proceeded with attachment selection and fabrication of prosthesis.

Overdenture attachment system

An attachment is a mechanical device used for the fixation, retention and stabilisation of a dental prosthesis³². Attachment resiliency is associated with the movement between the abutment and the prosthesis. The more directions in which the prosthesis can move, the less stress is placed on the implant & more forces to the residual ridge. That being said, the attachment is more resilient.

Various movements allowed by resilient attachments

Vertical movement occurs when prosthesis is moved bodily toward the tissue. Results in even loading and support from entire length of the residual ridge. Hinge

movement occurs when the prosthesis revolves around an axis that has been formed by the most posterior attachments on each side of the arch. Rotation movement occurs when the prosthesis rotates around an axis that runs anterior-posteriorly. Translation and spinning or fishtailing when the prosthesis moves in an anterior-posterior or a bucco-lingual direction, without any rotation. The prosthesis, in turn, revolves around a vertical axis. Combination of all movements.

Retention systems

Several retention systems for implant overdentures have been described in the literature. For mandibular overdentures supported by two implants, the implants can be interconnected with a bar or remain unsplinted. The first implant overdentures used a bar-clip attachment, but the use of unsplinted implants has increased. Currently, unsplinted implants with ball attachments are the most common system, but the choice of a specific system can be based more on subjective preferences than scientific evidence^{32–34}. Implant overdentures require substantial prosthodontic maintenance, especially during the first year of service. Magnets on unsplinted implants also have been used, but the retention is poorer which can influence patient satisfaction¹⁰.

Different attachment assemblies

Clips and bars, ball/ O-ring, magnets, studs, telescopic copings (rigid or non-rigid). Rigid telescopic copings transfer most of the masticatory forces to the supporting implants. This increases the risk for implant fatigue and eventual fracture of the implant or its components.

Bar and clip attachment system is used in a splinting manner, the other attachments may be used individually (non-splinted) or in combination with the bar system³¹. It has mainly two varieties as Bar joint (resilient), single sleeve, multiple sleeves, bar unit (non-resilient). They provide good retention and stability. The disadvantages are vertical dislodgement, maximum stress generation, technique sensitive, higher cost, maintenance and hygiene is difficult, frequent loosening of retentive clips. The ideal length of a single bar should be minimum of 20–22 mm to accommodate two clips, to provide adequate retention and support³⁵. The bar element that fits on the bar is in the form of a clip (sleeve/channel) that is attached to the fitting surface of the overdenture. The bar may have various cross-sections, such as round, a reverse U-shape (rigid joint) or egg-shape or circle (resilient joint). The bar may be made from pre-milled plastic patterns (castable bars like round bar, plastic dolder bar, I bar, EDS bar, hader bar), prefabricated like type IV gold, such as the Dolder® bar. It may also be produced by CAD/CAM technology from a block of commercial pure titanium. The denture stone cast and wax setup are scanned optically to get their exact 3D images. The information is sent to the milling machine to form the bar, it

reduces certain human errors therefore, bars are usually of high quality and are porosity free. Examples are the ISUS® bar (Dentsply Prosthetics), the Nobel Procera® implant bar overdenture (NobelBiocare), and CAM StructSure® precision milled bars (Biomet 3i). The bar should be rigid enough to prevent its distortion. The clip may be rigid, e.g., made of gold (Dolder®), or resilient (plastic i.e., Hader®)³¹. These bars are available in 0, 2, and 4 degrees for telescopic milled restorations. The bar castings should only be made with hard alloys.

Hader bar is a hinge resilient attachment, provides mechanical snap retention. Plastic clips are recommended than metal clips because removal of metal clips is difficult and requires more chair side time. Advantages of metal clips are, they are more resistant to wear, smaller bar dimensions can be used³⁵. The clip is made of nylon that has three different colour-coded retention strengths. In general, resilient clips are easy to replace and cheaper.

Dolder bar is a combination resilient attachments as they allow vertical and hinge movements. Due to its adjustability, it is easy to control the retention provided by the bar. It is best-indicated when the patient has adequate inter-arch space, and minimum resiliency and maximum retention is required³⁵.

Factors that influence the flexibility of the bar

Length & height of the bar, physical properties of the alloy, magnitude of the masticatory loads. anterior-posterior spread. In general, the distal cantilever should not exceed more than half of the anterior-posterior distance³⁵. Two implants are usually placed in a straight-line relationship and ideally on the crest of the ridge. A single straight bar is suitable in a square arch, a minimum of 12 mm of vertical restorative space is usually required with this system.

Ball/O-ring attachment systems

This system consists of a retentive patrix, which is part of an abutment has the shape of a small ball with different diameters and is made of metal alloy. The system also has a matrix, which is attached to the fitting surface of the denture and into which the patrix fits. The matrix can be composed of metal or resilient nylon. In one ball attachment system known as the O-ring attachment, a plastic ring is fitted in a groove inside a metal ring or socket, which is housed in the fitting surface of the denture. The advantages are easy of maintenance, low cost, minimal chair-side time, ease of replacement of elements if required^{14,18}. Disadvantages are, the patrix (ball) violates the vertical restorative space and are not suitable to use when the implants are not parallel (an angulation >15°). To overcome this disadvantage, locators were developed (Zest Anchors, Escondido, CA, USA) in 2001. Locators are classified as universal hinge. Examples of the ball attachment systems include the Dal-Ro® (BioMet 3i), the Dalbo (Dalbo-B® and

Dalbo-classic®), the dental precision (Cendres+Metaux) and the Preci-Clix® (Preat Corp.). In principle, the Preci-Clix® is similar to the Hader® clip as both systems have resilient (nylon) matrices³¹.

Magnetic attachments

They are universal resilient attachments. They provide vertical, hinge, translation, and rotation movements, and provides resistance only to movements away from the tissue. It offers 95% load relief. They are made up of aluminium-nickel-cobalt metals. These are not very successful because the magnetic forces of attraction were weaker. To overcome this, newer generation magnets were developed with improved properties of rare earth elements such as samarium and neodymium. The advantages are they are shorter compared to mechanical attachments so can be used in cases of reduced inter-arch space, in moderately nonparallel abutments since they do not follow a particular path of insertion, laboratory procedures are not necessary, more resilient and allow free movement. Disadvantages are, attachment needs to be removed before taking MRI because it causes streaking, heating during sterilization leads to decrease in retentive forces³⁵. These attachments get corroded in saliva with time.

Telescopic attachments

They provide rigid attachment hence can be used for immediate loading. Advantages are, excellent immobilization of the restoration, flexibility of design, easy maintenance of oral hygiene, relative independence of the individual attachments, a very high degree of retention and comparatively rigid connection to the abutments²⁸. Syncone system has virtually wear resistant attachments. It can also be used on angulated abutments³⁵. These attachments consist of a patrix, which is attached to the implant, and a matrix, which is contained within the fitting surface of the denture. Retention is achieved through frictional contact between the matrix and the patrix may be increased with time as a result of the increased adaptation disadvantage is the technically challenging, time consuming, high cost^{28,35}, bulkiness of the crowns, unsatisfactory esthetic treatment outcome³⁶, and require adequate inter-arch space.

Attachments with resilient patrices

Certain movements can occur in the joint, due to the fabrication material of the patrix element (nylon). Widely used resilient attachment is called Locator® (Locator abutments, Zest Anchors). The locator attachment system consists of an abutment, which is attached to the implant and contains a matrix. It also has a patrix element that is a polymer (nylon) insert, which is housed in a metal cap and provides retention. The cap is attached to the fitting surface of the denture and is made of

titanium alloy. Locator attachment features as a dual retention (frictional and mechanical). The mechanical retention is gained by a shallow undercut on abutment in which the outer margin of attachment is snapped. Therefore, the matrix, when fully seated in the matrix, engages the outer and inner surface of the matrix part (dual retention). Disadvantages are, they cannot be used where rigid restoration is required and regular replacement of male nylon part due to constant wear and tear³⁵. It can be used in cases of limited inter-arch space, and can accommodate inter implant angulations up to 40°.

Stud attachments are one of the oldest attachment systems. They can be divided into two groups, extraradicular, in which male component projects from the implant, intraradicular, in which the male component is a part of denture base. Ball attachment, locaters, O-ring attachments, extracoronary resilient attachments (ERAs) are rigid attachments, most commonly used, best suitable for parallel implants. The ERA attachment provides hinge and vertical resiliency. The fixed component of this attachment is made of titanium alloy with the female attachment portion coated with titanium nitride to decrease attachment wear. The female component comes with different gingival cuff heights: 2 mm, 3 mm, and 5 mm. The nylon male component is captured in the denture acrylic. Six color-coded males correspond to six levels of retention. In order from the least to the most retentive, they are white, orange, blue, gray, yellow, and red.

Fundamentals of bar arrangement

As a general rule, if a single bar is being utilized, the ideal length should be 20–22 mm to accommodate two clips/riders (means the center of the implants should be 24–26 mm apart if standard diameter 4 mm implants are being used).

The vertical distance between the bottom of the bar and soft tissue of alveolar ridge should be 2 mm or more. This distance allows easy passage of saliva and food particles and cleaning tools. If gap is 1 mm or less, it will cause plaque and calculus accumulation and difficulty in oral hygiene. If the bar is compressed, it causes hyperplasia of the gum. Sagittally, the bar should be positioned directly above the crest of the ridge. If the bar is positioned lingual of the ridge, it will interfere with tongue space and its function and the patient's speech, if placed labially, it will interfere with lip support.

Guidelines for denture base extension for implant supported overdenture

For tissue supported, the borders of the overdenture in the anterior area should not extend to the end of the sulcus, a minimum extension in the anterior region but maximum extension in stress-bearing areas such as buccal shelves, distally onto the retromolar pads and lingually onto the mylohyoid ridge. For tissue-implant-supported,

the borders of the overdenture are shorter than conventional dentures, however, they can't be eliminated since this type of prosthesis is still partly tissue supported. For fully implant-supported, since the prosthesis is completely implant born, flanges can be eliminated. Bilaterally balanced occlusion is given in implant-supported overdentures.

LAB PROCEDURES

Hader bar

In 1973, Helmut Hader (master technician and dental manufacturer), developed a unique attachment system that even today is mainly known in the USA as Hader Bar and Hader vertical. It is a semi-precision bar attachment that provides hinge movement. The function is based on the mechanical snap retention concept.

Three color-coded clips/riders are available with three retentive strengths. In order from the least to most retentive, they are white, yellow and red. Use of a metal housing with the Hader plastic clips/riders is strongly recommended. In addition to plastic clips/riders, the option of adjustable gold alloy clips/riders is available (Fig. 2).

Fabrication procedures for a castable hader bar attachment with plastic clips/riders

Make a full arch pick-up impression with a rigid impression material such as polyether, fabricate the master cast and select matching plastic UCLA abutments. Adjust the length of the plastic bar & connect the plastic bar to the UCLA abutments with wax, sprue the bar and UCLA abutments. Complete the casting procedure. Finish and polish the casting. Try the bar intraorally and radiographically for oral fit. Insert the bar on the master cast, snap plastic clips on the bar. Insert as many clips on the bar according to available space. Block out the undercuts. Duplicate cast is obtained from the master cast.

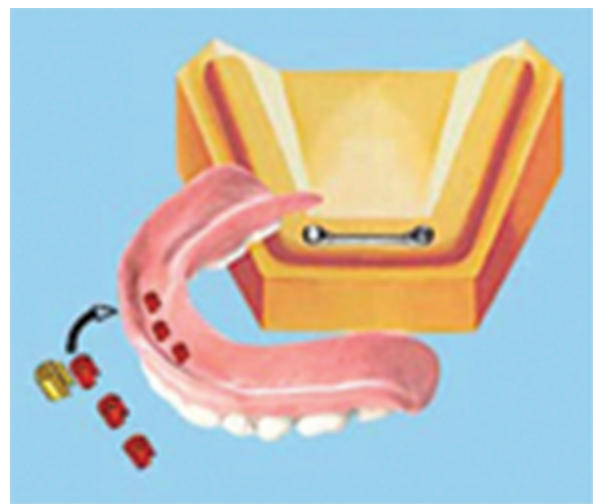

Fig. 2 Hader bar and Hader Vertical

Insert laboratory clips into the impression in the same position as the imprints of the actual clips and pour the impression. The laboratory clips will be held in the proper position in the duplicate cast by the extensions of the riders in the stone. Try the denture teeth arrangement intraorally and process it to get final prosthesis. Insert actual clips in their position in the denture base. Press the clips into the prepared receptacles in the acrylic denture base. There should be a snap when the clips are pushed into position. The clips are easily seated and can be easily replaced.

Dolder bar

It is a prefabricated precision bar attachment (it was developed by Dr. Eugen Dolder in Switzerland). It is available in two forms, rigid (U-shaped with parallel walls), which is also called a bar unit & resilient (egg-shaped and provides vertical and hinge resiliency). The resilient Dolder bar is also called a bar joint, which is made of gold alloy (Elitor). It is an adjustable bar. The Dolder bar should be soldered to the abutments, and the sleeve should be secured in the denture base with self-cure acrylic. Indicated in adequate inter-ridge space, when minimum resiliency, maximum retention is expected. Contraindicated in minimum inter-ridge space, patients with poor compliance in maintenance and oral hygiene & financial constraints³⁷.

Treatment success

Most studies available on mandibular overdentures report a success rate of 90 to 100 percent. A higher failure rate for maxilla, which is nine times greater than for mandible³⁸. If a distinction between the degree of atrophy in the maxilla and the bone quality is made, the results show that failure in the maxilla is a result of short implants, poor bone quality, and an inadequate number of implants³⁹. Since overdenture has more components (abutments, clips, bars, anchors, and female retainers), it carries a higher chance of complication. A five-year longitudinal study comparing two resilient attachment assemblies showed more complications with bars than with ball attachments. The psychological and physiological impacts⁴⁰, failure is directly proportional to smoking⁴¹.

Follow up and maintenance

Characteristics of ideal peri-implant tissues are pink, firm/adherent, keratinized tissue circumferentially around the implant, there should be no peri-implant mucocitis, peri-implantitis, resorption of the bone around the implant, recession, tissue overgrowth, calculus formation and retention. Home care implements, plaque-control implement, toothbrushes, end-tufted toothbrushes, access brush, interdental brushes, proxy tip, flossing cords, thornton bridge and implant cleaner, a nylon-woven flossing cord, denture brushes, denture

tablets and brushes must be used. Plastic reinforced scalers designed like a hoe or back-action chisel are ideal for these restorations, during office visits the overdenture should be placed in an ultrasonic bath with a chemical tarter-and-stain-remover solution. Antimicrobials chlorhexidine (0.12%) should be considered if the patient demonstrates peri-implant disease, recall visits and radiographically a baseline film at 6 months post loading, another 12 months later, and every 2 years thereafter at the crestal bone level, the bone-to-implant interface should be done.

SUMMARY

The main advantages over other treatment modalities are the patient satisfaction levels, which are high. The procedure is simple, and the prosthodontic treatment time is similar to that for conventional complete dentures. Various attachment systems can be used with similar success. Success is related both to a correct biomechanical design and maintaining a healthy oral environment. The focus is the successful placement of the implant, establishing osseointegration, building the restoration, proper biomechanics and healthy gingival tissues with adequate dimensions and contours that will allow for ideal maintenance. The overdenture is a good prosthetic option for patients who seek prosthesis stability and retention but do not mind that the prosthesis is removable. It is a boon for patients who do not have sufficient bone and soft tissue and require the benefits of bulk offered by such designs. In addition, the economics affected by placing minimal numbers of implants demand the trauma-sparing behaviour delivered by overdentures. Mandibular overdentures have been successful and there are many studies documenting this. Whereas failure rate is more for maxillary implant supported overdentures and further research is needed. The development of modern implant dentistry has been extremely rapid. The rapid changes of implant dentistry make it difficult to speculate on future directions of implant dentistry.

REFERENCES

1. Kurian BP, D'lima J, Karthikeyan CR, Mathew J, Paul T, Hareesh MT. Prosthetic efficiency of implant-supported overdentures with locator attachment: a clinical case report. *J Int Oral Health*. 2015;7:129–132.
2. Sharma R, Kumar A, Chopra D, Tewari D. Implant-supported overdenture. *J Dent Sci Oral Rehab*. 2014;5:139–141.
3. Schmitt A, Zarb GA. The notion of implant-supported overdentures. *J Prosthet Dent*. 1998;79:60–65.
4. Thomason JM, Kelly SA, Bendkowski A, Ellis JS. Two implant retained overdentures—a review of the literature supporting the McGill and York consensus statements. *J Dent*. 2012;40:22–34.
5. Mariano LOH, Sartori EA, Broilo JR, Shinkai SR, Corso L, Marczak RJ. Stresses in implant-supported overdentures with bone resorption: A 3-D finite element analysis. *Revista Odonto Ciência [serial online]*. 2012;27:41–46.

6. Carlsson GE. Clinical morbidity and sequelae of treatment with complete dentures. *J Prosthet Dent.* 1998;79:17–23.
7. Raghoebar GM, Meijer HJ, Stegenga B, van't Hof MA, van Oort RP, Vissink A. Effectiveness of three treatment modalities for the edentulous mandible. A five-year randomized clinical trial. *Clin Oral Implants Res.* 2000;11:195–201.
8. Allen, PF. A patient-based assessment of implant-stabilized and conventional complete denture. *J Prosthet Dent.* 2001;85:141–147.
9. Sadowsky SI. Mandibular implant-retained overdentures: a literature review. *J Prosthet Dent.* 2001;86:468–473.
10. van Steenberghe D, Quirynen M, Naert I, Maffei G, Jacobs R. Marginal bone loss around implants retaining hinging mandibular overdentures, at 4-, 8- and 12-years follow-up. *J Clin Periodontol.* 2001;28:628–633.
11. Branemark PI, Zarb GA, Albrektsson T, editors. *Tissue-integrated prostheses.* Chicago: Quintessence Publishing Company, Inc., 1985.
12. Batenburg RH, Meijer HJ, Raghoebar GM, Vissink A. Treatment concept for mandibular overdentures supported by endosseous implants: a literature review. *Int J Oral Maxillofac Implants.* 1998;13:539–545.
13. Payne AG, Solomons YF. The Prosthodontic maintenance requirements of mandibular mucosa- and implant-supported overdentures: a review of literature. *Int J Prosthodont.* 2000;13:238–245.
14. The Glossary of prosthodontic terms. *J Prosthet Dent.* 2005;94:10–92.
15. Liu J, Pan S, Dong J, Mo Z, Fan Y, Feng H. Influence of implant number on the biomechanical behaviour of mandibular implant-retained/supported overdentures: a three-dimensional finite element analysis. *J Dent.* 2013;41:241–249.
16. Radu CC. Implant supported overdentures. *Ann Facul Eng Hunedoara. J Eng.* 2009;VII:83–86.
17. Mangano C, Mangano F, Shibli JA, Ricci M, Sammons RL, Figliuzzi M. Morse taper connection implants supporting “planned” maxillary and mandibular bar-retained overdentures: a 5-year prospective multicenter study. *Clin Oral Implants Res.* 2011;22:1117–1124.
18. Pan YH, Lin TM, Liang CH. Comparison of patient's satisfaction with implant-supported mandibular overdentures and complete dentures. *Biomed J.* 2014;37:156–162.
19. Leles CR, Leles JL, de Paula Souza C, Martins RR, Mendonça EF. Implant-supported obturator overdenture for extensive maxillary resection patient: a clinical report. *J Prosthodont.* 2010;19:240–244.
20. Ha SR, Kim SH, Song SI, Hong ST, Kim GY. Implant-supported overdenture with prefabricated bar attachment system in mandibular edentulous patient. *J Adv Prosthodont.* 2012;4:254–258.
21. Kumar AVP, Vinni TK, Mahesh MR. Full mouth rehabilitation with maxillary tooth supported and mandibular tooth and implant supported combination prostheses: a 4-year case report. *J Indian Prosthodont Soc.* 2012;12:113–119.
22. Bryant SR, Walton JN, MacEntee MI. A 5-year randomized trial to compare 1 or 2 implants for implant overdentures. *J Dent Res.* 2015;94:36–43.
23. Emami E, Heydecke G, Rompré PH, de Grandmont P, Feine JS. Impact of implant support for mandibular dentures on satisfaction, oral and general health-related quality of life: a meta-analysis of randomized-controlled trials. *Clin Oral Implants Res.* 2009;20:533–544.
24. Jemt T. Failures and complications in 391 consecutively inserted fixed prosthesis supported by Brånemark implants in edentulous jaws: a study of treatment from the time of prosthesis placement to the first annual checkup. *Int J Oral Maxillofac Implants.* 1991;6:270–276.
25. Ueda T, Kremer U, Katsoulis J, Mericske-Stern R. Long-term results of mandibular implants supporting an overdenture: implant survival, failures, and crestal bone level changes. *Int J Oral Maxillofac Implants.* 2011;26:365–372.
26. Yueh-Ling Chao, Li-Deh Lin, Tong-Mei Wang. Mandibular rehabilitation with dental implants: a case report. *J Prosthodont Implantol.* 2012;1:53–59.
27. Bornstein MM, Cionca N, Mombelli A. Systemic conditions and treatments as risks for implant therapy. *Int J Oral Maxillofac Implants.* 2009;24:12–27.
28. Vogel RC. Implant overdentures: a new standard of care for edentulous patients current concepts and techniques. *Compend Contin Educ Dent.* 2008;29:270–276.
29. Misch CE. *Contemporary Implant Dentistry.* 3rd ed. USA: Elsevier Publications; 2007.
30. Warreth A, Alkadhimi AF, Sultan A, Byrne C, Woods E. Mandibular implant-supported overdentures: attachment systems, and number and locations of implants – Part I. *J Ir Dent Assoc.* 2015;61:93–97.
31. Bergendal T, Engquist B. Implant-supported overdentures: a longitudinal prospective study. *Int J Oral Maxillofac Implants.* 1998;13:253–262.
32. Naert I, Gizani S, Vuylsteke M, Van Steenberghe D. A 5-year randomized clinical trial on the influence of splinted and unsplinted oral implants in the mandibular overdenture therapy. Part I: Peri-implant outcome. *Clin Oral Implants Res.* 1998;9:170–177.
33. Goffredsen K, Betty H. Implant-supported mandibular overdentures retained with ball or bar attachments: a randomized prospective 5-year study. *Int J Prosthodont.* 2000;13:125–130.
34. Davis DM, Packer ME. Mandibular overdentures stabilized by astra tech implants with either ball or magnets: 5 year results. *Int J Prosthodont.* 1999;12:222–229.
35. Krishna Prasad D, Anupama Prasad D, Buch M. Selection of attachment systems in fabricating an implant supported overdenture. *J Dent Implant.* 2014;4:176–181.
36. Kao DW, Fiorellini JP. An interarch alveolar ridge relationship classification. *Int J Periodontics Restorative Dent.* 2010;30:523–529.
37. Hoffmann O, Beaumont C, Tatakis DN, Zafiroopoulos GG. Telescopic crowns as attachments for implant supported restorations: a case series. *J Oral Implantol.* 2006;32:291–299.
38. Hutton JE, Heath MR, Chai JY, Harnett J, Jemt T, Johns RB, et al. Factors related to success and failure rates at 3-year follow-up in a multicenter study of overdentures supported by Brånemark implants. *Int J Oral Maxillofac Implants.* 1995;10:26–44.
39. Chan MF, Närhi TO, de Baat C, Kalk W. Treatment of the atrophic edentulous maxilla with implant-supported overdentures: a review of the literature. *Int J Prosthodont.* 1998;11:7–15.
40. Friberg B, Jemt T, Lekholm U. Early failures in 4,641 consecutively placed Brånemark dental implants: a study from stage 1 surgery to the connection of completed prostheses. *Int J Oral Maxillofac Implants.* 1991;6:142–146.
41. Bain CA, Moy PK. The association between the failure of dental implants and cigarette smoking. *Int J Oral Maxillofac Implants.* 1993;8:1–13.