

Hemolytic Anemia Drugs Induced by Antihypertensive Agents: A case of Laboratory

Aurelian Udristioiu^{1*}, Radu G. Iliescu², Manole Cojoraru³

¹Emergency County Hospital Târgu Jiu., Clinical Laboratory, Department of Hematology, Romania.

²Polytechnic Institute of New York University, Department of Researches, Brooklyn, New York.

³Titu Maiorescu University, Medicine Faculty, Physiology, Bucharest.

*Corresponding Author's Email: aureliamu2007@yahoo.com

Abstract: Hemolytic anemia drugs induced are rare and, clinical laboratories are often required to provide the optimal serological tests to confirm the diagnosis. Some of the mechanisms involved in hemolytic anemia drugs are controversial. Unfortunately, most of the drugs that cause acute, severe intravascular hemolysis and sometimes renal failure, disseminated intravascular coagulation and death, seem to work by different mechanisms, and usually involve drug-dependent antibodies that activate the complement with pancytopenia or agranulocytosis in peripheral blood. This study confirms a case study of hemolytic anemia drugs induced by antihypertensive agents.

Keywords: Antiglobulin test, epitopes, hemolytic anemia, hemolysis

INTRODUCTION

Anemia most often is discovered through laboratory tests, but the history and physical examination can provide important clues about the presence of hemolysis and its underlying cause [1]. Drug-dependent antibodies are those antibodies that will only react in vitro in the presence of drug (eg, bound to RBCs or added to the patient's serum in test systems to detect drug antibodies); these are antibodies directed at epitopes on the drug and/or its metabolites, or a combination of drug plus RBC membrane protein. The mechanisms involved in the serological and clinical findings are controversial.

CASE REPORT

A 58 year woman patient, since 8 years in treatment with drugs for chronic cardiovascular disease, was admitted to the county hospital, in department of Cardiology in January month, because of clinical symptoms of cardiovascular disease. The patient complained dyspnea and fatigue and, occasionally, back pain and the skin may appeared with easy jaundice. In a resting tachycardia with a flow murmur was presented and on image of ultrasound CT, the enlarged liver and spleen reflected a hepatic steatosis and hypersplenism.

In history patient was noted that in medication prescribed along of five years for Hypertension were encompassed two drugs with a potential effect side of hemolytic anemia, Trezen (Perindopril) and Chindin. These drugs can cause serious side effects which include; headache, dizziness and lightheadedness, fatigue, dry, tickling cough, weakness, numbness or tingling in the arms, legs or feet, nausea, taste disturbances itching, rash or increased sweating and hemolytic anemia after some years. After preclinical investigations of screening, without a concluded

diagnosis, the currant doctor from cardiology recommended the special analyses regarding the discovery of signs and symptoms of anemia.

Laboratory blood , CBC, showed: HGB = 8.3 g/d L (n=12.6- 14 mg/dl); HTC = 24.8% (n= 37-47%); RBC = 1.85 $\mu\text{L} \times 10^3$ (n = 3.8-5.8 $\mu\text{L} \times 10^3$), PLT = 166 $\mu\text{L} \times 10^3$ (n = 150-450 $\mu\text{L} \times 10^3$), WBC = 4.3 $\mu\text{L} \times 10^3$ (n= 4-10 $\mu\text{L} \times 10^3$), Reticulocyte = 14 % (n = 0.5-1.2%). Erythrocyte indices with abnormal values (MCV = 133.7 f L (n = 82-92 f L), MCH = 45 pg (n = 27-31 pg); MCHC= 36.6 g/dl (n = 32-36 g/dl).

Peripheral blood smear findings: on blood smear in optic microscopy was registered, Band = 0, Segmented = 55.2%, Eosinophile = 4.5%; Basophile = 0.5%, Lymphocyte = 36.6%, Monocyte = 3.2%, ESR = 55 mm/h.; Suspect flags on coulter HMX Analyser: No signal.

Other laboratory tests relieved an increased level LDH = 710 u/l (n = 313 – 618), glucose = 151 mg/dl (n = 75 – 110 mg/dl), urea = 50.5 mg/dl (n = 17-43 mg/dl), creatinine = 1.26 mg/dl, triglyceride = 575 mg/dl (20 – 150), iron = 139 ug/dl (N = 49 – 181), serum ferritin = 15 ng/ ml, Total bilirubin = 2.4 mg/dl (n = 0.20-1.30 mg/dl), Conjugate bilirubin = 0.6mg/dl (n = 0.0=0.30 mg.dl), Indirect bilirubin = 1.8 mg/dl (n = 0.0-1.10mg/dl), Delta Bilirubin = 0.6 ((n = 0.0-0.5 mg/dl), ALT= 33.6 U/L (n = 5-31 U/L), AST = 61.0 U/L, (N = 5-32 U/L). APTT (activate prothrombin time), PT/PTT (prothrombin time/partial thromboplastin time) with normal results.

DISCUSSION

Along with anemia, a characteristic laboratory feature of hemolysis is reticulocytosis, the normal

response of the bone marrow to the peripheral loss of red blood cells. In the absence of concomitant bone marrow disease, a brisk reticulocytosis should be observed within three to five days after a decline in hemoglobin. In a minority of patients, the bone marrow is able to chronically compensate, leading to a normal and stable hemoglobin concentration. The anemia of hemolysis usually is normocytic, although a marked reticulocytosis can lead to an elevated measurement of mean corpuscular volume, because the average mean corpuscular volume of a reticulocyte is 150 f.

The more common extravascular hemolysis is the removal and destruction of red blood cells with membrane alterations by the macrophages of the spleen and liver. Circulating blood is filtered continuously through thin-walled splenic cords into the splenic sinusoids with hypersplenism because of hemolytic anemia which involved the following preclinical features, after abnormal and accelerated destruction of red cells.

Increased breakdown of hemoglobin, resulted in: increased bilirubin level (mainly indirect-reacting) with jaundice of urinary urobilinogen, hemoglobinemia, hemoglobinuria and hemosiderinuria. The level of lactate dehydrogenase (LDH) in the blood is elevated), haptoglobin levels was decreased.

Peripheral blood smear microscopy emphasis: fragments of the red blood cells ("schistocytes"), some

red blood cells may appear smaller and rounder than usual (spherocytes). The direct Coombs test was positive, hemolysis being caused by an immune process. The balance between red cell destruction and marrow compensation determined the severity of anemia. Hemosiderin in the urine indicated a chronic intravascular hemolysis and also urobilinogen in the urine was increased as a biological effect.

In the specialty lecture, the most acceptable one involves drugs, like penicillin, that covalently bind to proteins (eg, RBC membrane proteins); RBCs become coated with drug *in vivo* and, a drug antibody (usually IgG) attaches to the drug-coated RBCs that are subsequently cleared by macrophages. The most controversial is the so-called immune complex mechanism, which has been revised to suggest that most drugs are capable of binding to RBC membrane proteins, but not covalently like penicillins [2].

The direct antiglobulin test (DAT), also known as the direct Coombs' test, demonstrates the presence of antibodies or complement on the surface of red blood cells and is the hallmark of autoimmune hemolysis. The patient's red blood cells are mixed with rabbit or mouse antibodies against human IgG or C3. Agglutination of the patient's antibody- or complement-coated red blood cells by anti-IgG or anti-C3 serum constitutes a positive test. Red blood cell agglutination with anti-IgG serum reflects warm AIHA, while a positive anti-C3 DAT occurs in cold AIHA (Figure 1).

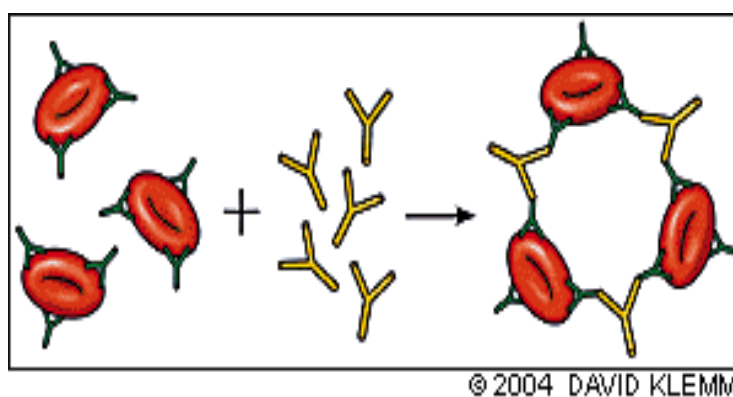


Fig.1: Direct antiglobulin test, demonstrates the presence of autoanti-bodies (shown here) or complement on the surface of the red blood cell

There are two types of drug-related antibodies. Drug-independent antibodies are those antibodies that can be detected *in vitro* without adding any drug; thus, *in vitro* and *in vivo* characteristics are identical to cell red blood cell (RBC) autoantibodies. The prototype drug is methyl dopa, which causes the production of RBC autoantibodies in about 15% of the patients receiving the drug, but only about 0.5% to 1% develop an HA [3, 4].

The FDA reported on 85 cases of cefotetan-induced HA from approval of cefotetan in 18% were

fatalities [5] Mean fall in hemoglobin (Hb) level was 6.7 g/dL, with mean final Hb of 5.2 g/dL. Hydrocortisone antibodies have been detected in individuals without HA (6). A recent finding should be of interest to hematologists: the first case of a DIIHA due to hydrocortisone has been described (7). This adds another possible explanation for poor responses to steroid therapy in some cases of AIHA where steroid-induced DIIHA may be masked by the autoimmune process (Table 1).

Table 1: Selected Drugs that Cause Immune-Mediated Hemolysis

Mechanism	Drug absorption (hapten)	Immune complex	Autoantibody
DAT Site of hemolysis Medications	Positive anti-IgG Penicillin, Ampicillin, Methicillin, Carbenicillin Cephalothin (Keflin)* Cephaloridine (Loridine)*	Positive anti-C3 Quinidine, Phenacetin , Hydrochlorothiazide , Rifampin (Rifadin) , Sulfonamides, Isoniazid, Quinine, Insulin, Tetracycline, Melphalan (Alkeran), Acetaminophen, Hydralazine (Apresoline), Probenecid, Chlorpromazine (Thorazine), Streptomycin, Fluorouracil (Adrucil), Sulindac (Clinoril)	Positive anti-IgG Extravascular Alpha-methyl dopa, Mefenamic acid (Ponstel), L-dopa, Procainamide, Ibuprofen, Diclofenac, (Voltaren) Interferon

In our case of this study, in drug prospects of Trezen and chinidin, as side effect is written hypersensitivity reactions: rash and thrombocytopenia, rare pancytopenia and agranulocytosis. Occasionally there have been reports of photosensitivity and lupus erythematosus-like syndrome.

Differential diagnosis was made with Glucose-6-phosphate dehydrogenase deficiency with can lead to

hemolysis in the presence of oxidative stress. Hereditary spherocytosis which is characterized by spherocytes, a family history, and a negative direct antiglobulin test. Sickle cell anemia and thalassemia which are hemoglobinopathies characterized by chronic hemolysis. When and iron deficiency is severe the anemia is hypochromic and microcytic but in milder degrees of iron deficiency the anemia is normocytic (Figure 2).

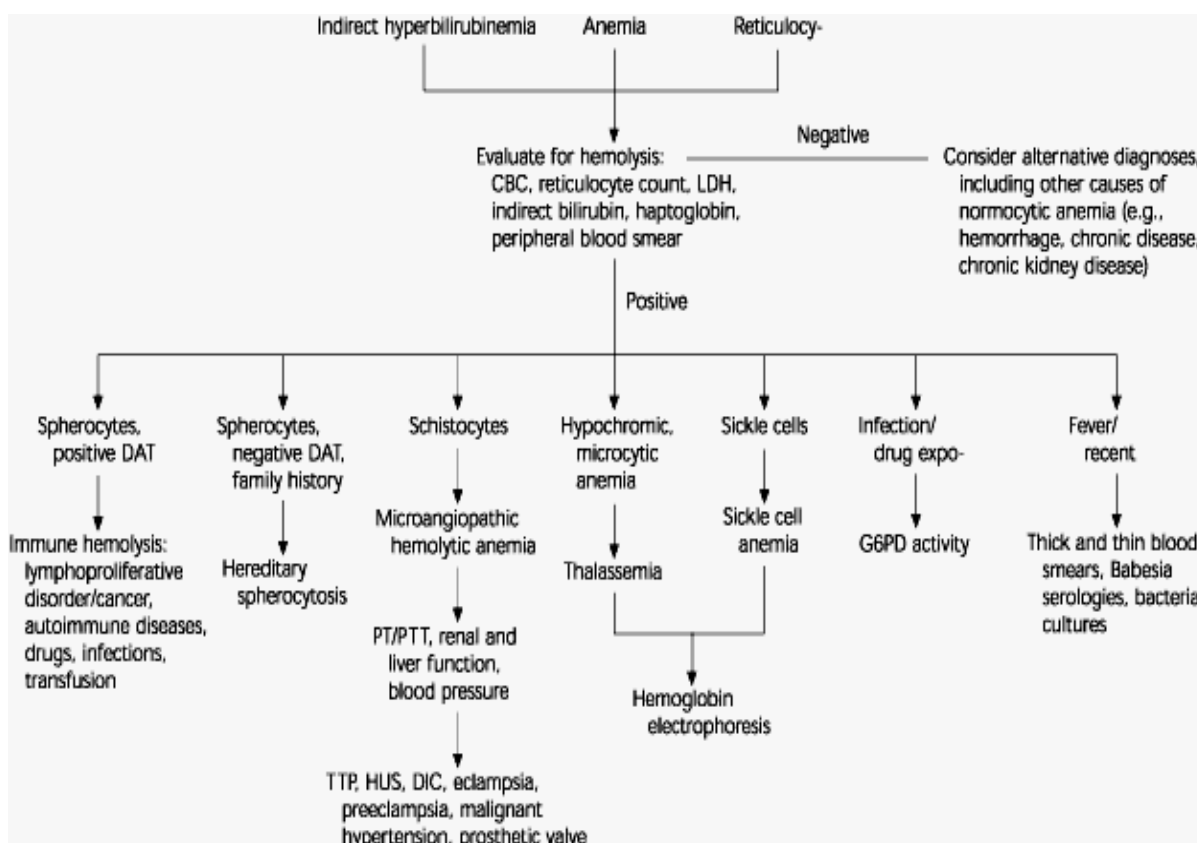


Fig. 2: Algorithm for the evaluation of hemolytic anemia

(CBC = complete blood count; LDH = lactate dehydrogenase; DAT = direct antiglobulin test; G6PD = glucose-6-phosphate dehydrogenase; PT/PTT = prothrombin time/partial thromboplastin time; TTP = thrombotic thrombocytopenic purpura; HUS = hemolytic uremic syndrome; DIC = disseminated intravascular coagulation)

In the megaloblastic anemia, the anemia is normocytic and is not associated with leucopenia, thrombocytopenia in peripheral blood. Macrocytes and ovalocytes can be also presented on blood film, differently, Hemolytic Anemia where appear Poikilocytosis and Heintz body in erythrocytes (Figure 3).

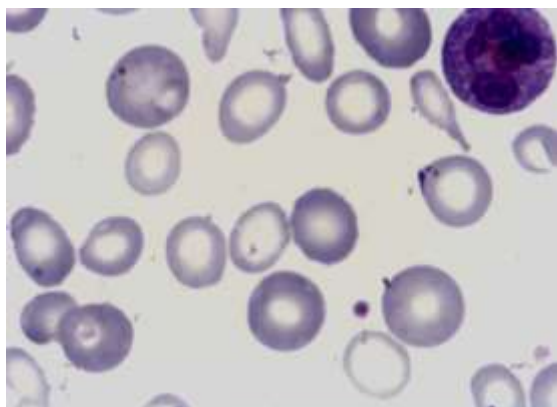


Fig. 3: Poikilocytosis and Heintz body in Eritrocytes (Hemolytic Anemia)

Deficiency of vitamin B12 or folic acid also leads to the production of giant metamielocytes and multi-segmented macropolycytes. The abnormalities in the granulocytic series do not disappear as promptly as then megaloblasts after specific therapy and their present may be helpful in diagnosis. To microscopic examination of slide from bone marrow, can occurred the hyperplasic series of erythrocytes ~ 45%, deficiency of erythropoiesis, poly-cromathopil and acidophil erythroblasts with megaloblastic character, large metamielocytes and giant band forms

CONCLUSION

The combined membrane plus drug can create an immunogen; the antibodies formed can be IgM or IgG and often activate complement, leading to acute intravascular lysis and sometimes renal failure; fatalities are more common in this group. It is still unknown why and how some drugs induce RBC autoantibodies, sometimes causing AIHA.

REFERENCES

1. Dhalival G, Cornett AP, Tiernely ML; Hemolytic Anemia. Am Fam Physician, 2004; 69(11): 2599-2607.
2. Garratty G; Drug-induced immune hemolytic anemia. ASH Education Book, Volume 1, 2009: 73-79.
3. Petz LD, Garratty G; Immune Hemolytic Anemias. 2nd edition, Philadelphia: Churchill Livingstone, 2004:261- 317.
4. Garratty G, Arndt P, Prince HE, Shulman IA; The effect of methyl dopa and procainamide on suppressor cell activity in relation to red cell autoantibody production. Br J Haematol., 1993; 84(2): 310–315.
5. Viraghavan R, Chakravarty AG, Soreth J; Cefotetan-induced haemolytic anaemia. A review of 85 cases. Adv Drug React Toxicol Rev., 2002; 21(1-2):101–107.
6. Umlas J, Turner LA; Antibodies to hydrocortisone in reagent red cells causing positive antibody screening tests. Transfusion, 1993; 33(8): 686–688.
7. Martinengo M, Ardenghi DF, Triopdi G, Reali G; The first case of drug-induced immune hemolytic anemia due to hydrocortisone. Transfusion, 2008; 48(9): 1925-1929.