

JOURNAL OF THE PUNJAB ACADEMY OF FORENSIC MEDICINE & TOXICOLOGY

Volume 6, 2006

Contents:

• From Editor's Desk	2
• Editorial	
Fundamentals of management of sexual assault cases	3
• Papers	
Estimation of stature and sex from foot print length using regression formulae and standard foot print length formula respectively	5
D V Oberoi, A Kuruvilla, KM Saralaya, A Rajeev, B Ashok, Nagesh KR, NG Rao	
Futility of post-mortem examination in 'brought in dead' cases: a retrospective study	9
B.D.Gupta, P.C.Vaghela, Gambhir Singh, Rahul Mehta	
• Reviews	
Few tips for making ground sections of teeth for research purpose	11
Amandeep Singh, R K Gorea, Urveshi Singla	
Age estimation: a dental approach	14
Shamim T, Ipe Varghese V, Shameena PM, Sudha S	
Donation of bodies for cadaveric dissection in medical colleges	17
Prakash, Latha V. Prabhu, Anu V. Ranade, Sampath Madhyastha, Gajendra Singh	
The Criminal Law (Amendment) Bill, 2003: an overview	20
Shilekh Mittal, Dildar Singh	
Role of forensic medicine in mass casualty incident	25
B. R. Sharma, Harshabad Singh	
Continued medical education (CME) programmes: some observations	31
D.S.Bhullar	
Review of intermediate syndrome in organophosphorous poisoning	34
Vikram Palimar, K M Saralaya, Arun M	
• Case Report	
Medical termination of pregnancy by ayurveda practitioner - negligence or crime?	36
Lavlesh Kumar, S. S. Agarwal	
Case report – death due to battering of child	39
J.S.Dalal, H.R.Tejpgal, Ashok Chanana, Puneet Khurana, Navpreet Kaur	
An unusual case of pain abdomen	41
SS Oberoi, Anil Garg	
An unusual case of homicide by radioactive material	43
R.K.Gorea, K.K. Aggarwal, Mrinal Jha, Anil Garg	
Role of superimposition technique in practice of forensic medicine	45
Pathak Akhilesh K, Mangal H.M.	
• Letters to the Editor	48
• Achievements Of Members	49

COPY RIGHT: No part of this publication may be reprinted or republished without the prior permission of PAFMAT. Submission of all papers to the journal is understood to imply that it is not being considered for publication elsewhere. Submission of multi-authored paper implies that the consent of each author has been obtained. In this journal, every effort has been made not to publish any inaccurate or misleading information. However, the Editor and Joint Editor accept NO LIABILITY in consequences of such statements.

Address request for reprint or further information relating to any article may please be made with author and in case of multi-author, please communicate to the first author.

Printed and Published by: Dr. R. K. Gorea and Dr. Hakumat Rai on behalf of
Punjab Academy of Forensic Medicine & Toxicology
At Zenith Design World, Near India Gift House, 22 No. Phatak, Patiala. Mobile 9872666799

AN UNUSUAL CASE OF PAIN ABDOMEN

Dr SS Oberoi, Associate Professor,
Dr Anil Garg, Junior Resident,
 Department of Forensic Medicine, Govt. Medical College, Patiala

Abstract

A young woman aged 25 years with two children and wife of army personnel came to the military hospital with alleged history of pain abdomen since early morning. There was no history of vomiting and diarrhoea. Patient was treated conservatively, but died within an hour. The body was sent for post-mortem examination to Mortuary, Government Medical College, Patiala. On opening the abdomen, the abdominal cavity was found containing 3.5 litres of blood and all the abdominal viscera were examined and found to be normal. Uterus was found to be having through and through perforation in its right postero-lateral wall caused by a pointed object.

Key words: Uterus, Perforation, Haemorrhage.

Introduction

Pain abdomen can be due to multiple factors like appendicitis, colitis, amoebic liver abscess, gallstones, ectopic pregnancy rupture and some complications of the abortion. In spite of the MTP act 1971 in force, still a number of illegal abortions are taking place. These are mostly done by unqualified medical practitioners and in the villages even by quacks. Most of the illiterate persons willing for abortion visit these unqualified practitioners due to easy approach, low cost and for secrecy. These days, the unmarried girls who get pregnant, also fall pray to these unscrupulous elements. If everything goes well, there is no problem. But in the hands of these unqualified practitioners, the chances of complications are more and in extreme form death may ensue and then the problem may arise both for the kith and kin of deceased and for these unqualified medical practitioners.

Case History

The deceased was a 25-year-old female, wife of army personnel. She was married for the last seven years and had two sons aged 5 years and 2 years.

As per the history given by her husband, she was perfectly well the pervious day and on next day at 6 AM, she complained of pain abdomen and some uneasiness. She was taken to the army hospital by her husband at 6.35 AM.

As per the record of the army hospital, on examination, she was restless,

her general condition was fair, and she was afebrile. Pallor was present. Injection ranitidine was given and blood samples were taken for Hb determination and other investigation and patient suddenly collapsed at 6.50AM and declared dead.

The body was brought for post-mortem examination on the same day. On external examination, there was nothing abnormal, except marked pallor of the body. On internal examination, all the body organs were found extremely pale, all the chambers of the heart and big vessels were empty and abdominal cavity was full of blood (about 3.5 litres).

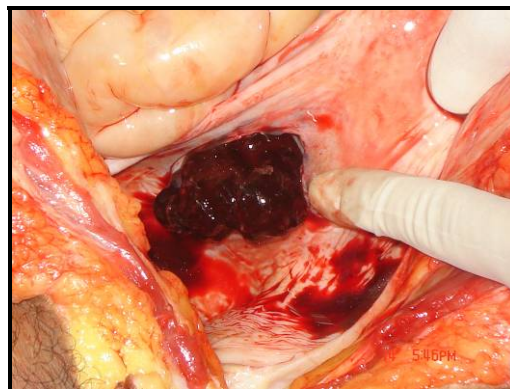


Figure 1: Blood visible on opening abdominal cavity.

On examination of the uterus, it was found enlarged in size measuring 13cm x 9cm x 4cm. The endometrium was found to be eroded and there was through and

through perforation in the right postero-lateral wall below the right fallopian tube.

Discussion

Perforation of the uterus though rare, still is not an uncommon complication of abortion. In the present case, the patient's chief complaint as per her husband was pain abdomen and due to obvious reasons, they do not give any history of abortion. The cause of death as mentioned in the PMR was haemorrhagic shock due to perforation of the uterus by a pointed instrument and the uterine finding i.e. the size of the uterus and eroded endometrium suggested attempted abortion. If the patient had provided the proper history and got the proper medical treatment in time, she could have been saved.

Conclusion

The need of the hour is to make the MTP act more people friendly. Therefore, the patients can approach the qualified medical practitioners without any hesitation and seek proper medical treatment and thus a number of life's can be saved.

References

1. Parikh CK. Parikh's textbook of medical jurisprudence, forensic medicine and toxicology. 6th ed. New Delhi, India: C.B.S. Publisher and Distributors; 2004. p. 5.56-60.
2. Rao NKG. Textbook of Forensic Medicine and Toxicology. Delhi, India: Jaypee Brothers Medical Publishers (P) Ltd; 2000.p. 314-20.
3. Reddy KSN. The essentials of forensic medicine and toxicology. 24th ed. Hyderabad, India: K Saguna Devi; 2005. p. 355-63.
4. Subrahmanyam BV. Forensic medicine, toxicology and medical jurisprudence. New Delhi, India: Modern Publishers; 2004. p. 105-12.
5. Vij K. Textbook of forensic medicine and toxicology principles and practice. 3rd ed. New Delhi, India: Elsevier, a division of Reed Elsevier India Pvt. Ltd; 2005. p. 545-58.

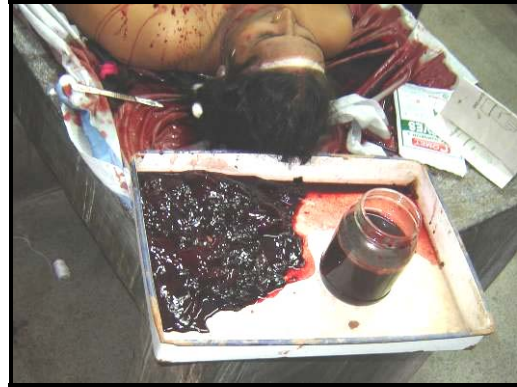

Figure 2: The volume of blood removed from abdominal cavity.

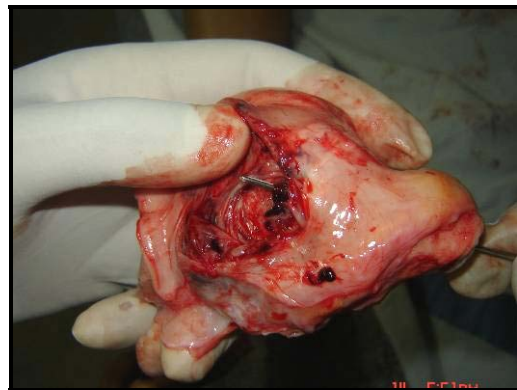


Figure 3: The perforation in the uterus.

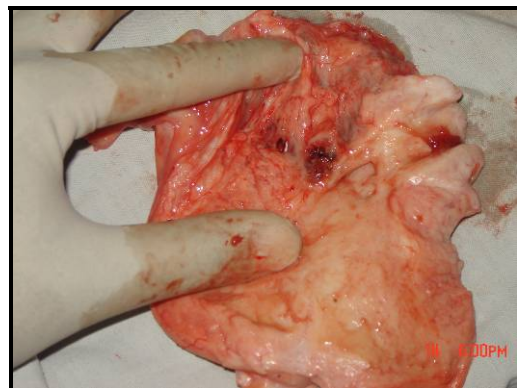


Figure 4: The uterus opened up to showing the perforation and erosions.