

## Primary Ewing's Sarcoma of Spine, Its Management & Outcome: A Retrospective Analysis

Somil Jaiswal\*, Manish Jaiswal\*, Pooja Jaiswal\*\*, Chhitij Srivastava\*\*\*, Sunil Kumar Singh\*\*\*\*, Anil Chandra\*\*\*\*, Bal Krishna Ojha\*\*\*\*\*

### Abstract

*Objective:* Primary Ewing's Sarcoma (ES) of spine is rare entity but causes significant morbidity if not diagnosed in time and not managed properly, so the optimal management of primary Ewing's Sarcoma spine should be analysed to improve the final outcome. *Patients & Methods:* We retrospectively analysed eight cases of spine ES who had been operated in last 8 years in one of the tertiary centre of northern India. *Result:* Male: female ratio was 7:1. Most common presenting symptoms was paraparesis in all 8 patients. Most common site of spine involvement was dorsal spine in all patients. MRI spine showed lobulated lesion well demarcated and enhancing, extending in paravertebral tissue in six out of eight cases. Histopathological examination of specimens after surgical decompression from all patients showed small blue round cell tumors, arranged in sheets. CD99 was positive in all the cases. One patient developed recurrence after 2 years of surgery and further lost follow up. 5 patients died (one immediate due to surgical complication, one early chemo-radiation phase due to neutropenia and subsequent septicemia & 3 patients at 9, 13 and 15 months of primary surgery. Only two out eight patients were recurrence free who had undergone chemo-radiation after surgery. *Conclusion:* Primary Ewing's sarcoma of spine has poor outcome even after surgical decompression and chemo-radiation as multimodality management. Strict follow up is must for improving the outcome.

**Keywords:** Ewing's Sarcoma Spine; CD99; Spinal Tumour; Round Cell Tumour.

### Introduction

Primary Ewing's Sarcoma (ES) of the spine are rare and is the second most common primary bone tumour in paediatric patients accounting for 4% of childhood malignancies [1]. Its peak incidence is seen in the second decade of life and commonly presents with swelling and pain of the affected bone. The most commonly involved bones are femur, pelvis and the long bones of the extremities. Vertebrae are affected in less than 5% of the cases [2]. Primary vertebral

Ewing's sarcoma has been categorized into sacral and non-sacral types based on the differences in the treatment responses and survival rates. Primary involvement of the non-sacral spine represents approximately 0.9% of all cases. Low back pain is the most common symptom followed by a palpable swelling and may present with nerve root or spinal cord compression [1,2].

Spinal cord compression can produce neurological deficits depending on the tumor location, but is often a delayed presentation. Definitive diagnosis requires cytological and immune-histochemical analysis. The prognosis is usually poor. However, multimodality therapy has increased the 5 year survival rate to about 40%. To date, the number of reported cases of ES with primary localization on spine in adult patients remains small and they are all sporadic reports [1,2,3,4,5].

This is the reason why there are still several concerns about the optimal treatment especially in adults. Here we analyse eight cases of dorsal spine ES and review literature on it.

**Author's Affiliation:** \*Assistant Professor \*\*\*Additional Professor \*\*\*\*Professor \*\*\*\*\*Professor & Head, Department of Neurosurgery, King George's Medical University, Lucknow, U.P., India. \*\*Assistant Professor, Department of Pathology, Integral Institute of Medical Sciences & Research, Lucknow, U.P., India.

**Reprint Request:** Manish Jaiswal, Assistant Professor, Department of Neurosurgery, King George's Medical University, Chowk, Lucknow, U.P., India-226003.

E-mail: [manishjaiswal@kgmcindia.edu](mailto:manishjaiswal@kgmcindia.edu)

Received on 31.12.2016, Accepted on 09.01.2017

## Patients and Methods

### Patient Details and Preoperative Workup

The data for eight patients with primary ES of the spine who had been surgically treated in one of the tertiary care center of northern India since 2008, were

analyzed retrospectively. The demographic data, clinical details, radiological features, management and outcome were compiled and analyzed (**Table 1**). All patients had preoperative plain and contrast computed tomography (CT) scan spine and magnetic resonance imaging (MRI) spine.

**Table 1:** Clinical Summary of Cases having Primary Ewing's Sarcoma spine

No.	Age/ Sex	Symptoms/ Signs & Its Duration	CT* / MRI* Spine	Surgery	Chemo- Therapy	RT*	HPE*	Outcome
1.	11yr/ M	Both Lower limb Weakness, BBI, Hypoesthesia Below L2 20 Days	Extradural Neoplasm At Level Of D12 To L1/L2 Level	D11/12 L1/L2 Laminectomy With Sub Total Removal Of Tumor	Y*	Y	ES*	Recurrence At 2 Years
2.	27yr/ M	Gradually Increasing Swelling Over Upper Back, Both Lower limb Weakness, BBI present, 2 Months 10 Days 3 Days	Large Destructive Soft Tissue Contrast Enhancing Lesion On Left Side Extending From D4 To D8 Vertebral Level with Destruction Pf Posterior Elements Of D5/6/7/8with Extension Into Right Paraspinal Soft Tissues.	D5 /6/7 Laminectomy With Decompression Of Tumour	Y	Y	ES	Expired After 15 Months Of Primary Surgery
3.	12yr/ M	Progressive Weakness Of Both Lower limb Hypaesthesia Below D12 No BBI 1 Month	Soft Tissue Lesion Extending From D10 To L1 Vertebral Level & Left Paravertebral Region	D10/11/12/L1 Laminectomy With Removal Of Sub Total Removal Of Epidural Lesion	Y	Y	ES	Expired After 13 Months Of Primary Surgery
4.	40yr/ M	Progressive Weakness Of Both Lower limb BBI present, Hypesthesia Below D6 6 Month 4 Months	Collapse Of D4 Vertebral Body With Large Pre/ Para Vertebral & Posterior Epidural Soft Tissue Leading To Dorsal Compressive Myelopathy At D3 To D5 Level	Posterolateral Thoracotomy With D4 Spondylectomy With D3 Laminectomy & D3- D5 Titanium Cage & Plating	N	N	ES	Expired In Post Op Period
5.	11yr/ F	Progressive Weakness Of Both Lower limb Hypesthesia Below D8 2 Weeks	Neoplastic Etiology? Nerve Sheath Tumor	D5/6/7 Laminectomy With Evacuation Of Organised Abscess From D5- D7 Epidural Space	Y	Y	ES	Recurrence Free After 12 Months Of Primary Surgery
6.	14yr/ M	Fever Weakness Both Lower limb Hypesthesia Below L1 15 Days 10 Days	Collapse D11 Vertebra With Well Defined Pre & Para Vertebral Soft Tissue with Contrast Enhancement Extending From D9/10 Upto D11/12with Compressive Myelopathy	D11& D12 Laminectomy With Evacuation Of Abscess	Y	Y	ES	Expired After 9 Moths
7.	32yr/ M	Weakness Of Both Lower Limb BBI present 2 Months 1month	Contrast Enhancing Posterior Epidural Soft Tissue Lesion Extending From D1 To D7 Leading To Myelopathic Changes, Extending Along B/L Neural Foramina At D4/5 Level With Involvement Of Posterior Element S Of D4	D4/5/6 Laminectomy With Subtotal Removal Of Lesion	Y		ES	Expired After 1 Month Due To Sepsis
8.	13yr/ M	Back Pain Weakness Of Both Lower limb Hypesthesia Below D3 BBI present 1 Month 20 Days 15 Days	Ill Defined Homogenously Enhancing Posterior Extradural Lesion Extending From D4 To D7 Level With Extension Through Neural Foramina B/L At D4/5, D5/D6 & D6/D7 Levels Into Paraspinal Muscles	D3 To D6 Laminectomy With Subtotal Excision Of Sol	Y	Y	ES	Recurrence Free After 9 Months Of Primary Surgery

\*CT=Computed tomography, MRI= Magnetic Resonance Imaging, RT= Radiotherapy, Y= Yes, ES= Ewing's Sarcoma, BBI= Bladder Bowel Involvement

### *Surgical Management*

All patients underwent tumor excision as radical as possible, within the safe limits. Relevant laminectomies were done. Tumor was excised as much as possible. The infiltrated dura was not opened if it was not breached by the tumor. However, if it was breached, the infiltrated dura was excised radically and repaired using fascia lata graft.

### *Diagnosis*

Histopathological examination in all case showed round cell tumor. Periodic acid Schiff staining was done in all cases. CD99 staining was done to confirm Ewing's sarcoma. Staining for Vimentin, Synaptophysin, Chromogranin and Desmin was carried out.

### *Adjuvant Therapy*

Following the radical excision, the patients received induction chemotherapy with two cycles of Cyclophosphamide (1,200 mg/m<sup>2</sup>) plus Vincristine (1.5 mg/m<sup>2</sup>) plus Adriamycin (75 mg/m<sup>2</sup>), alternating with Ifosphamide (1,800 mg/m<sup>2</sup>) and Etoposide (100/m<sup>2</sup>) administered at 3 weeks. Eight weeks later, the local area was irradiated with 40-50 Gy radiotherapy. This was followed by eight cycles of chemotherapy, with the same drugs as for induction chemotherapy, at 3-week intervals.

### *Follow-up*

The patients underwent follow-up monitoring, on an outpatient basis, at monthly intervals. To avoid loss at follow-up, the telephone numbers (mobile numbers) and complete addresses of the patients and the relatives were noted. Thus, the information was acquired telephonically, especially in patients who expired.

## **Results**

### *Clinical Presentation*

The youngest patient was 11 years old and the oldest was 40 years. There were five patients in the 2nd decade, one in the 3rd decade, and two patient in the 4th decade. Of the eight patients, only one was female. The duration of presenting symptoms was between 20 days and 6 months. Paraparesis was the presenting symptom in all eight patients and was the commonest symptom. Sensory disturbance was seen in five patients. Bladder disturbance was seen in three

patients. One patient each had swelling at the back (**Fig. 1**) and back pain as complaints.

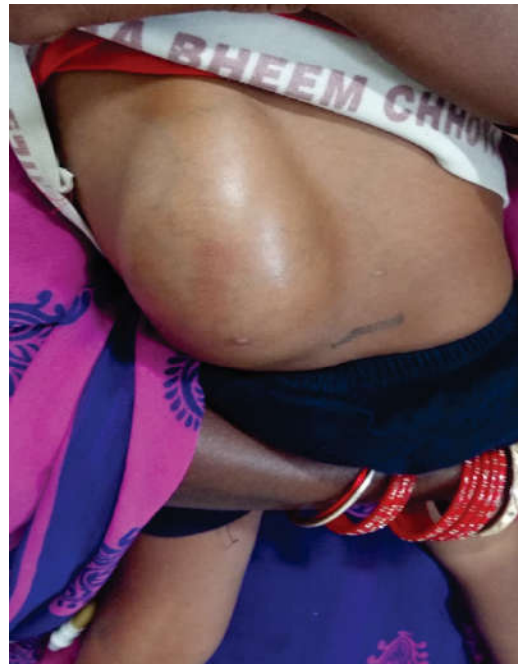The differential diagnosis for these spinal space occupying lesions with acute onset weakness of lower limbs were: (1) metastasis; (2) Pott' spine, which is common in India (3) bony lesions like eosinophilic granulomas, bony hemangiomas, and sarcomas.

### *Radiology*

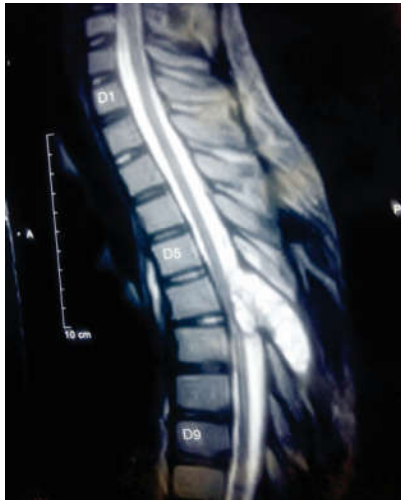CT scan spine showed that the dorsal spine was the commonest bone to be involved in all patients. The spinous process, lamina, pedicles or vertebral body were involved, in combination or alone. There was erosion of the bone and osteoblastic activity (reactive sclerosis) of the bone at places. Lytic lesions were seen on plain radiographs and onion peeling was not seen. MRI spine showed lobulated lesion well demarcated and enhancing; extending in paravertebral tissue in six out of eight cases (**Fig. 2**, **Fig. 3** and **Fig. 4**). Skeletal surveys in all patients were normal.

### *Pathology*

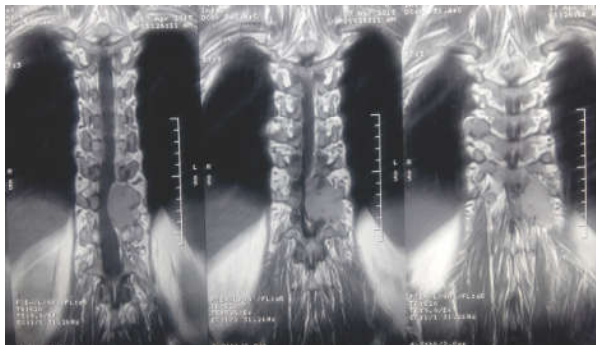
Histopathological examination of specimens from all patients showed small blue round cell tumors (**Fig. 5**). The tumor cells were arranged in sheets, and few pseudo-rosettes were seen. Staining of the tissue with periodic acid-Schiff (PAS) stain revealed the presence of glycogen granules. CD99 was positive in all the cases (**Fig. 6**).



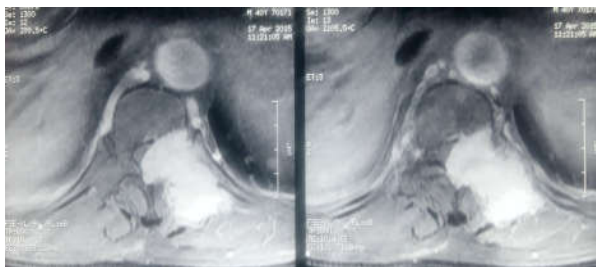
**Fig. 1:** Swelling over back in Primary Ewing's Sarcoma Spine Patient



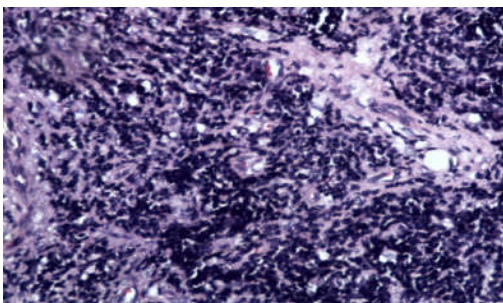
**Fig. 2:** T2 weighted MRI Spine Sagittal view showing hyperintense multi-lobulated mass involving posterior element of dorsal spine causing cord compression



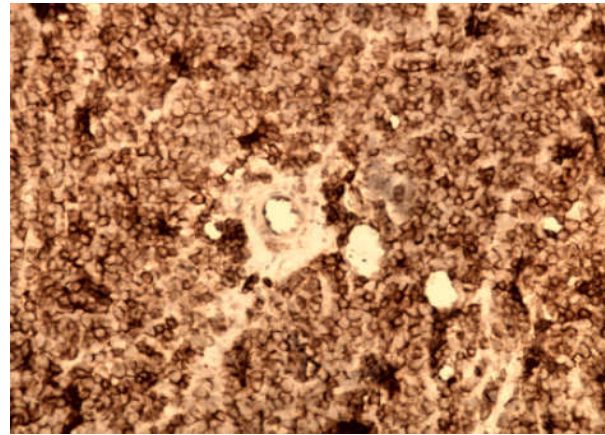
**Fig. 3:** T1 weighted MRI Spine Coronal view showing iso to hyper-intense mass involving dorsal spine with cord compression in Ewing's Sarcoma spine patient



**Fig. 4:** Contrast MRI Spine axial view showing homogenous enhancing mass involving dorsal spine and extending into paraspinal region and intraspinal cord compression in Ewing's Sarcoma spine patient



**Fig. 5:** Tumour section showing small round cells (H&E, x 400)



**Fig. 6:** Tumour cells showing strong membranous staining for CD99 (immune-peroxidase, x400)

### Follow-up

The follow-up periods ranged from 3 months to 2 years at the time of review. One patient had recurrence after 2 years of primary surgery but refused re-surgery and was lost to follow-up. Three patients died after full course of chemo-radiation, at 9, 13 and 15 months of primary surgery. One patient died in the immediate post-operative period due to operative complications. Another patient died during the early course of chemo-radiation due to sepsis secondary to neutropenia. Two patients had undergone chemo-radiation and are recurrence-free at 9 and 12 months after primary surgery.

### Discussion

Primary Ewing's sarcoma of the spine is extremely rare. Grubb et al in 1994 had retrospectively analysed 36 patients of primary Ewing's Sarcoma of the spine detailing demographic, clinical characteristics, pathology and outcome [6].

Spinal ES has male predominance along with young age onset [6,7]. Average age of presentation was 20 years ranging from 11 years to 40 years. Major complaint in the form of weakness of limbs was of short duration and ranged from days to less than 6 months along with local pain and palpable mass. Possibility of spinal malignancy should be kept in mind in patients in the first two decades of life and symptoms consisting of severe local pain along with tenderness not relieving on best rest. These tumours are commonly seen at thoracic levels but can occur at any levels of the spine [6,7,8,9,10].

The differential diagnosis of a small round-cell bone tumour includes, in addition to Ewing's sarcoma, neuroblastoma, primitive neuroectodermal tumour of bone (PNET), malignant

lymphoma, and rhabdomyosarcoma [11,12].

In all the eight cases the diagnosis was established by histopathology and immunohistochemistry. The characteristics features of PNET by histopathology and immunohistochemistry include: (1) poorly differentiated small round or spindle-shaped cells, densely packed or in sheets or nests (2) positive for neuronal or glial markers like CD99.

Plain radiographic signs of ES are late to appear, usually after the neurological signs have become obvious [13,14,15]. The most common finding was lytic bone destruction involving the vertebra. CT spine is of great value in determining the extent of involvement of both the vertebral bodies and the posterior elements as well as in outlining the soft tissue component. CT-guided needle biopsy of vertebral or paravertebral lesions can be accomplished with accuracy and relative ease. MRI spine is very sensitive in the early detection of ES in the spine. MRI spine is superior for visualizing epidural compression and tumour spread to the bone marrow or extension into adjacent soft tissues. The relationship of tumour to adjacent vasculature can also be determined.

In view of the limited number of reported cases, the optimal treatment for spinal ES has not yet been defined [16,17,18,19,20,21]. Surgical excision and decompression is the primary mode of treatment [22, 23,24,25,25]. Neurologic improvement is often noted in most of the patients following surgery [22,25,26, 27,28,29]. Spinal irradiation and hyper-fractionated radiotherapy of the tumour region have been shown to be of benefit [2,4,30,31]. Though there is no agreement on the chemotherapy regimens, successful results have been reported using combinations of Cyclophosphamide or Ifosfamide, Cisplatin or Carboplatin, Vincristine, Adriamycin and Etoposide [32,33,34,35]. Six out of eight patients were treated with postoperative radiotherapy and chemotherapy, and three are still alive and two patients are asymptomatic for 4-12 months. Despite the aggressive treatment with adjuvant radiotherapy and chemotherapy, most of the patients die within two years (range: 3 months-24 months). The combination of systemic and surgical treatment offers the patient a good chance of survival with a satisfactory quality of life. There is still a need for more clinical studies to explore reasonable strategies of treatment.

## Conclusion

Primary Ewing's sarcoma of spine is rare entity, involving dorsal spine most often. CD99 staining is positive in all pathological specimen of operated case.

It has poor outcome even after surgical decompression and chemo-radiation as multimodality management. Strict follow up is must for improving the outcome.

## References

1. Brat DJ, Parisi JE, Kleinschmidt-De Masters BK, Yachnis AT, Montine TJ, Boyer PJ, et al. Surgical neuropathology update: A review of changes introduced by the WHO classification of tumours of the central nervous system, 4th edition. *Arch Pathol Lab Med*, 2008; 132:993-1007.
2. Kampman WA, Kros JM, De Jong TH, Lequin MH. Primitive neuroectodermal tumours (PNETs) located in the spinal canal; the relevance of classification as central or peripheral PNET: Case report of a primary spinal PNET occurrence with a critical literature review. *J Neurooncol*, 2006; 77:65-72.
3. Akai T, Iizuka H, Kadayama S, Nojima T, Kohno M. Primitive neuroectodermal tumor in the spinal epidural space: Case report. *Neurol Med Chir (Tokyo)*, 1998; 38:508-11.
4. Athanassiadou F, Tragiannidis A, Kourti M, Papageorgiou T, Kotoula V, Kontopoulos V, et al. Spinal epidural extraskeletal Ewing's sarcoma in an adolescent boy: A case report. *Pediatr Hematol Oncol*. 2006; 23:263-7.
5. Aydin MV, Sen O, Ozel S, Kayaselcuk F, Caner H, Altinors N. Primary primitive neuroectodermal tumor within the spinal epidural space: Report of a case and review of the literature. *Neurol Res*. 2004; 26:774-7.
6. Grubb MR, Currier BL, Pritchard DJ, Ebersold MJ. Primary Ewing's sarcoma of the spine. *Spine*, 1994; 19:309-313.
7. Benmeir P, Sagi A, Hertzanu Y, Zirkin H, Rosenberg L, Peiser J, et al. Primary and secondary spinal epidural extraskeletal Ewing's sarcoma. Report of two cases and review of the literature. *Spine (Phila Pa 1976)* 1991;16:224-7.
8. Delattre O, Zucman J, Melot T, Garau XS, Zucker JM, Lenoir GM, et al. The Ewing family of tumors—A subgroup of small round-cell tumors defined by specific chimeric transcripts. *N Engl J Med*. 1994;331:294-9.
9. Fletcher CD, Unni KK, Mertens F. World Health Organization Classification of Tumors: Pathology and Genetics of Tumors of Soft Tissue and Bone. Lyon: IARC Press; 2002.
10. Gandhi D, Goyal M, Belanger E, Modha A, Wolffe J, Miller W. Primary epidural Ewing's sarcoma: Case report and review of literature. *Can Assoc Radiol J*. 2003; 54:109-13.
11. Harimaya K, Oda Y, Matsuda S, Tanaka K, Chuman H, Iwamoto Y. Primitive neuroectodermal tumor

- and extra skeletal Ewing sarcoma arising primarily around the spinal column: Report of four cases and a review of the literature. *Spine (Phila Pa 1976)*, 2003; 28:E408-12.
12. He SS, Zhao J, Han KW, Hou TS, Hussain N, Zhang SM. Primitive neuroectodermal tumor of lumbar spine: Case report. *Chin Med J (Engl)*, 2007; 120: 844-6.
  13. Hrabálek L, Kalita O, Svebisova H, Ehrmann J, Jr, Hajduch M, Trojanec R, et al. Dumbbell-shaped peripheral primitive neuroectodermal tumor of the spine: Case report and review of the literature. *J Neurooncol*. 2009; 92:211-7.
  14. Hsieh CT, Chiang YH, Tsai WC, Sheu LF, Liu MY. Primary spinal epidural Ewing sarcoma: A case report and review of the literature. *Turk J Pediatr*. 2008; 50:282-6.
  15. Izycka-Swieszewska E, Stefanowicz J, Debiec-Rychter M, Rzepko R, Borowska-Lehman J. Peripheral primitive neuroectodermal tumor within the spinal epidural space. *Neuropathology*. 2001; 21:218-21.
  16. Kadri PA, Mello PM, Olivera JG, Braga FM. Primary lumbar epidural Ewing's sarcoma: Case report. *ArqNeuropsiquiatr*. 2002; 60:145-9.
  17. Kaspers GJ, Kamphorst W, van de Graaff M, van Alphen HA, Veerman AJ. Primary spinal epidural extraosseous Ewing's sarcoma. *Cancer*. 1991; 68: 648-54.
  18. Kennedy JG, Eustace S, Caulfield R, Fennelly DJ, Hurson B, O'Rourke KS. Extraskelatal Ewing's sarcoma: A case report and review of the literature. *Spine (Phila Pa 1976)*, 2000; 25:1996-9.
  19. Kiatsoontorn K, Takami T, Ichinose T, Chokyu I, Tsuyuguchi N, Ohsawa M, et al. Primary epidural peripheral primitive neuroectodermal tumor of the thoracic spine. *Neurol Med Chir (Tokyo)*, 2009; 49: 542-5.
  20. Kinsella TJ. Extraskelatal Ewing's sarcoma. *J ClinOncol*. 1993; 1:489.
  21. Kogawa M, Asazuma T, Iso K, Koike Y, Domoto H, Aida S, et al. Primary cervical spinal epidural Extraosseous Ewing's sarcoma. *ActaNeurochir (Wien)*, 2004; 146:1051-3.
  22. Kumar R, Reddy SJ, Wani AA, Pal L. Primary spinal primitive neuroectodermal tumor: Case series and review of the literature. *PediatrNeurosurg*. 2007; 43:1-6.
  23. Louis DN, Ohgaki H, Wiestler OD, Cavenee WK. WHO Classification of Tumors of the Central Nervous System. 4th ed. Lyon: IARC; 2007.
  24. Mukhopadhyay P, Gairola M, Sharma M, Thulkar S, Julka P, Rath G. Primary spinal epidural extraosseous Ewing's sarcoma: Report of five cases and literature review. *Australas Radiol*. 2001; 45:372-9.
  25. Musahl V, Rihn JA, Fumich FE, Kang JD. Sacral intraspinal extradural primitive neuroectodermal tumor. *Spine J*. 2008; 8:1024-9.
  26. N'Golet A, Pasquier B, Pasquier D, Lachard A, Couderc P. Extraskelatal Ewing's sarcoma of the epidural space. A report of two new cases with literature review (author's transl) *Arch AnatCytol Pathol*. 1982; 30:10-3.
  27. Ozdemir N, Usta G, Minoglu M, Erbay AM, Bezircioglu H, Tunakan M. Primary primitive neuroectodermal tumor of the lumbar extradural space. *J NeurosurgPediatr*. 2008; 2:215-21.
  28. Ozturk E, Mutlu H, Sonmez G, Vardar Aker F, CinarBasekim C, Kizilkaya E. Spinal epidural extraskelatal Ewing sarcoma. *J Neuroradiol*. 2007; 34:63-7.
  29. Scheithauer BW, Egbert BM. Ewing's sarcoma of the spinal epidural space: Report of two cases. *J NeurolNeurosurg Psychiatry*. 1978; 41:1031-5.
  30. Sevick RJ, Johns RD, Curry BJ. Primary spinal primitive neuroectodermal tumor with extraneural metastases. *AJNR Am J Neuroradiol*. 1987; 8:1151-2.
  31. Sharma BS, Khosla VK, Banerjee AK. Primary spinal epidural Ewing's sarcoma. *Clin Neurol Neurosurg*. 1986; 88:299-302.
  32. Shin JH, Lee HK, Rhim SC, Cho KJ, Choi CG, Suh DC. Spinal epidural extraskelatal Ewing sarcoma: MR findings in two cases. *AJNR Am J Neuroradiol*. 2001; 22:795-8.
  33. Simonati A, Vio M, Iannucci AM, Bricolo A, Rizzuto N. Lumbar epidural Ewing sarcoma. Light and electron microscopic investigation. *J Neurol*. 1981; 225:67-72.
  34. Smith DR, Hardman JM, Earle KM. Metastasizing neuroectodermal tumors of the central nervous system. *J Neurosurg*. 1969; 31:50-8.
  35. Spaziante R, de Divitiis E, Giamundo A, Gambardella A, Di Prisco B. Ewing's sarcoma arising primarily in the spinal epidural space: Fifth case report. *Neurosurgery*. 1983; 12:337-41.
-