

Lanz Incision is Superior than Mcburneys Incision in Open Emergency Appendicectomy – Cosmetically & Also for Approach to the Base of an Appendix

M. Balachandar

Associate Professor of Surgery, Karpagam Faculty of Medical Sciences & Research Center, Coimbatore - 641 032.

Abstract

Appendicitis is one of the commonest acute surgical diseases and treatment by emergency open appendicectomy is the most frequently performed surgical procedure in many centers.

On review of more than 100 cases, around 50% of cases proceeded with McBURNEYS Incision, another 50% cases we have done with Lanz incision. We found Lanz incision is superior in the approach to the base of the appendix & also cosmetically better for the both male & female and also for the children.

The study has been done in the various hospitals where I worked both in India & Abroad.

Government Royapettah Hospital from September 1982 to May 1987, Coimbatore Medical college Hospital from June 1987 to April 1991, Government Head quarters Hospital, Erode from September 1991 to December 2000, Perundurai Medical College Hospital, Perundurai from November 2002 to July 2004.

In Saudi Arabia- from 2004 to 2008, Maldives in 2015, in Botswana in 2016.

Keywords: Lanz Incision; Mcburneys Incision; Appendicectomy.

Introduction

In most of the time, when we are doing Emergency

Corresponding Author: M. Balachandar, Associate Professor of Surgery, Karpagam Faculty of Medical Sciences & Research Center, Coimbatore - 641 032.
E-mail: saimarabala@gmail.com

Received on 31.12.2016, Accepted on 06.01.2017

appendicectomy, *open method* will be preferable because of the adhesions, some times appendicular mass or highly placed sub hepatic position or perforated gangrenous appendix. Also in a teaching institutions, it is easy for the Post graduates to do appendicectomy rather than by laparoscopy.

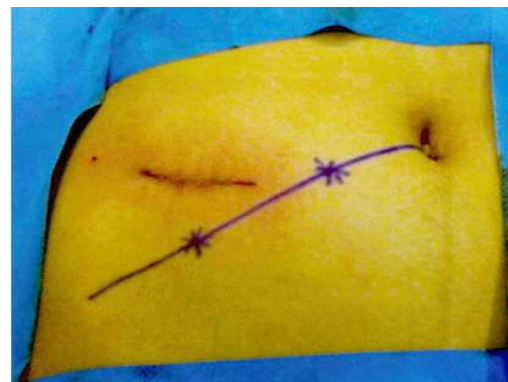Commonly McBURNEYS incision is preferred, but this is cosmetically not good, so we did a study compared with Lanz incision which is better cosmetically.

Method

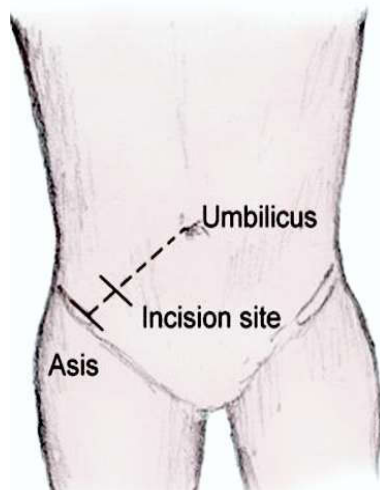
The Lanz incision transversely crosses McBurney's point (the junction of the middle and outer thirds of a line joining the right anterior superior iliac spine and the umbilicus. So scar is better than the Classical McBURNEYS incision cosmetically. Also approach to the base of the appendix is good in Lanz incision.

McBurney's Incision

An incision is made perpendicular to the McBURNEYS point. This is also known as a gridiron



Lanz
Incision
L



McBURNEYS Incision

or McBurney's incision.

We did more than 100 cases of open emergency Appendicectomies, out of which 50 % we did by McBURNEYS, other 50% we have done with Lanz incisions.

Discussion

Comparing the both incisions in open emergency Appendicectomies, we found approach to the base of appendix is easy with Lanz, also it is cosmetically better for the both sexes of adult & children.

In highly placed Sub hepatic appendix, we come across in 2 cases, the Lanz Incision is extended up by curvilinear & minimal muscle cutting, easily

approached the appendix with better cosmetically than the McBURNEYS incision conversion to Rutherford muscle cutting approach.

Also scar is good in Lanz, while compared to McBURNEYS, because of the transverse incision.

Conclusion

By this study, we are confirming the Lanz incision is better & superior than the McBURNEYS incision in open emergency Appendicectomies, in view of cosmetically a good scar both for female and male, also in children & easy approach to the base of the appendix.

References

1. McBurney, C. Experience with early operative interference in cases of disease of the vermiform appendix. *New York Medical Journal*. 1889; 21:676-684.
2. D. Hedge, S.D. Hedge, Variables in right iliac fossa anatomy and their relevance to appendicectomy: improving knowledge and practices *Clinical Anatomy*, 2008; 21:165-170.
3. R.M. Kirk *General surgical operations* (5th ed.) Church Livingstone, London 2006.p.107-108.
4. V. Naraynsingh, M.J. Ramdass, J. Singh, R. Sing-Rampaul, D. Maharaj McBurney's point: are we missing it? *Surgical and Radiologic Anatomy*, 2002; 24:363-365.
5. S. Benjamin Managing acute appendicitis, *BMJ*, 2002; 325:505-506.