

Caesarean Scar Site Pregnancy (CSP): A Rare Case Report

Dr. Naik Amit Sharad^{1*}, Dr. Chadha Mandeep², Dr. Naik Saudamini Amit³

¹Assistant Professor, SMBT, Institute of medical sciences, Maharashtra, India

²Senior Resident, SMBT, Institute of medical sciences, Maharashtra, India

³Assistant Professor, SMBT, Institute of medical sciences, Maharashtra, India

*Corresponding author

Dr. Naik Amit Sharad

Article History

Received: 29.05.2018

Accepted: 10.06.2018

Published: 30.06.2018

DOI:

10.21276/sjmcr.2018.6.6.2



Abstract: Intramural pregnancy with implantation of Gestational sac fully or partially within a scar caused by previous cesarean section is probably the rarest location for ectopic pregnancy. This type of pregnancy is prone for complications like uterine rupture and life threatening hemorrhage and hypovolemic shock during pregnancy or curettage. True incidence of pregnancy occurring in uterine scar has not been determined because so few cases have been reported in literature. We present a case of 28 yrs. G4P2L2A1 with 6wks amenorrhea presenting to gynecology OPD with PV bleeding and USG suggestive of incomplete abortion with products of conception in cervicoisthmic region. During the procedure of D & C severe bleeding was encountered and procedure was abandoned, tamponade done with Foleys catheter insertion into the uterine cavity. Systemic methotrexate was given to treat it but patient continued to bleed per vaginally and have lower abdominal pain. The amount of bleeding increased over a period of 2 days. Due to ongoing bleeding and in view of complete family hysterectomy was planned. During laparotomy, uterus was of 8-10 weeks size with a soft purplish black mass protruding through the lower uterine segment immediately above the internal os. This mass was intimately apposed and adherent to the bladder wall at the site of C. scar. The mass was of 5 x 4 cm size. Cervix was normal with no growth and the uterine cavity was empty in the fundal region. The finding confirmed the diagnosis of scar pregnancy which was reconfirmed by the HPE report.

Keywords: Intramural pregnancy, abdominal pain, laparotomy.

INTRODUCTION

Intramural pregnancy with implantation of Gestational sac fully or partially within a scar caused by previous cesarean section is probably the rarest location for ectopic pregnancy. This type of pregnancy is prone for complications like uterine rupture and life threatening hemorrhage and hypovolemic shock during pregnancy or curettage. True incidence of pregnancy occurring in uterine scar has not been determined because so few cases have been reported in literature. The incidence reported is of 1 in 1800 and 1 in 2500 pregnancies. The incidence is on rise due to rise due to rise in cesarean rate and better diagnostic modalities for earlier detection. The diagnosis is made on USG and confirmed by MRI or during laparotomy and or laparoscopy.

CASE

A 28 year old female presented to OBGY OPD with chief complaints of 6wks months amenorrhea with bleeding per vaginum on and off since 10- 12 days. Her obstetric history included previous 2 LSCS, the first was done for postdated pregnancy 8 years back and second was done 5 years back. She underwent a D& E 4 yrs back for unwanted pregnancy. She was not

using any contraceptive method. General physical examination was normal except for pallor. On per speculum examination blood stained mucous discharge was present. On bimanual examination uterus was retroverted, soft and bulky and bilateral fornices were free with no tenderness. On investigation UPT was positive with Hb 9.2g%, Beta HCG 1000.6. USG s/o ill-defined heterogeneous lesion with tiny cystic spaces noted in the anterior myometrium in the region of lower part of uterus with increased vascularity surrounding the lesion. Patient was taken for D& C in view of RPOC's. There was profuse bleeding on dilation of cervix hence procedure was abandoned and intrauterine Foleys catheter was introduced. After balloon inflation no active bleeding was seen. Two pints of PCV were transfused. USG was repeated and did not show any endometrial/ peritoneal collection with no evidence of perforation. Injection methotrexate was given the next day. Repeat β HCG level after methotrexate was 406. Intrauterine catheter was removed after two days. Patient started complaining of PV spotting from evening. The amount of bleeding increased over a period of 2 days. Due to ongoing bleeding and in view of complete family hysterectomy was planned.

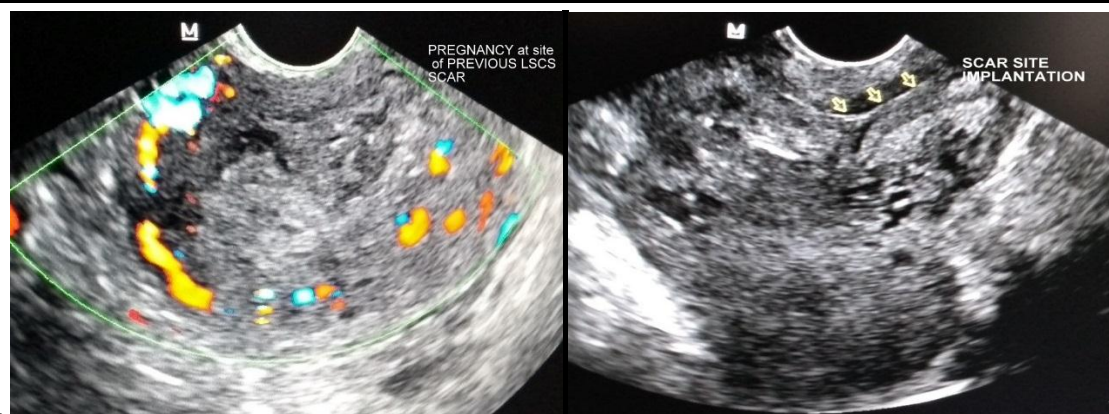


Fig-1&2: DOPPLER & USG IMAGES

During laparotomy, uterus was of 8-10 weeks size with a soft purplish black mass protruding through the lower uterine segment immediately above the internal os. This mass was intimately apposed and adherent to the bladder wall at the site of C. scar. Bladder was separated by sharp dissection. The cornual structures were ligated and cut bilaterally. Uterus was bisected and the products of conception were removed

from the lower uterine segment from the previous scar site. The mass was of 5 x 4 cm. Cervix was normal with no growth and the uterine cavity was empty in the fundal region. The procedure was continued and hysterectomy done. The finding confirmed the diagnosis of scar pregnancy which was reconfirmed by the HPE report.

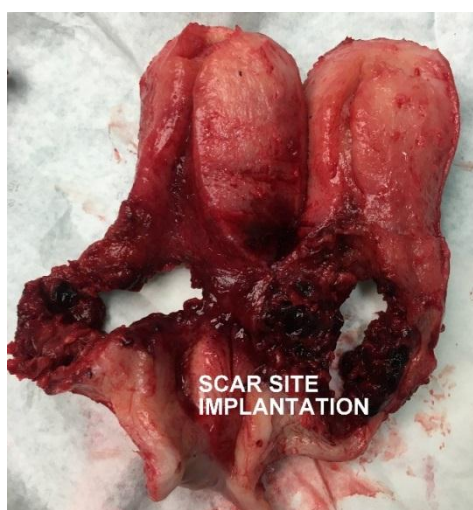

Fig-3: hysterectomy specimen confirming scar site ectopic pregnancy

DISCUSSION

A gestational sac in a previous LSCS scar is the rarest form of ectopic pregnancy and its diagnosis requires a very high index of suspicion. The first case was reported by Larsen *et al.* in 1978 and since then the incidence is on a rise due to rising incidence of cesarean section. A recent case series estimates an incidence of 1:2226 of all pregnancy with a rate of 0.15% in women with previous cesarean section and a rate of 6.1% of all ectopic pregnancy [1]. It has been hypothesized that the conceptus invades into the myometrium through a microscopic defect created through trauma that occurred in association with Lscs[2]. Hence cesarean section, any uterine surgery, manual removal of placenta [3], D&C[4], adenomyosis, embryo transfer and IVF [5] are all risk factors for scar site ectopic gestation. Our patient had history of previous two LSCS

and a dilatation and curettage which could have been the predisposing factors for her Scar site ectopic [3, 4]. Jurkovic *et al.* [6] found that 72% of their patients had undergone multiple (≥ 2) cesareans. According to his opinion number of previous LSCS is a risk factor for in scar implantation due to increased surface area. LSCS done for indications like malpresentation and or elective LSCS where the lower segment is not formed also increase the risk of blastocyst implantation in the scar as the healing process is hampered. So in consistent with the findings of this study our patient was at risk due to previous 2 elective LSCS done for CPD & postdated pregnancy with patient not in labour [3,4,6]. The published literature reveals that upto 13.6% scar site pregnancies are misdiagnosed as either inevitable miscarriages with a low lying sac or cervical pregnancy⁷. Gestational age at diagnosis ranges from

5+0 to 12 +4 weeks [8]. Clinical diagnosis of an early pregnancy implanted in a previous Caesarean scar can be very difficult, it may occasionally be delayed until the uterus ruptures and the patient experiences life-threatening bleeding [5,9]. Diagnosis should be based on the pregnant patient's history (H/O previous LSCS), positive pregnancy test and sonographic finding. The sonographic/Doppler flow criteria for diagnosis [10]-: 1. Empty uterine cavity and empty endocervical canal. 2. Gestational sac present in the lower part of the uterus or at the site of previous scar with or without fetal pole. 3. Absent or thin myometrial layer between the chorionic/gestational sac and unusually close proximity to the bladder wall. 4. Abundant blood flow around the G. sac rarely, the typical sonographic appearance of arteriovenous malformation (AVM) can be seen [11].

USG with Doppler are very reliable tools for diagnosing such cases [11,12]. Our patient's USG was s/o ill-defined lesion in the lower part of the uterus measuring approximately 5 x 4 cm with tiny cystic spaces with increased vascularity on Doppler flow. The USG findings were s/o incomplete abortion and hence the decision of dilatation and curettage was taken but on dilating the cervix the patient started bleeding profusely hence the procedure was abandoned bimanual compression was given with 40 units of Pitocin iv, as the bleeding continued foley's catheter was introduced and balloon inflated and the bleeding stopped. Similar case was reported by jukorvic *et al* and timor *et al.* [6,7]. Studies have shown that failed CSP's are generally more vascular than intrauterine miscarriage, which is sometimes referred to in the literature as transient 'uterine arteriovenous malformation' [13]. The foley's catheter controlled the bleeding and now the diagnosis of scar ectopic was made and the vitals being stable patient was given inj methotrexate 50 mg /kg. Studies have shown that a patient with CSP who is hemodynamically stable can be offered local or systemic methotrexate therapy [8,9]. Similar to our case chaung *et al.* used methotrexate with Foleys balloon tamponade for the treatment of CSP [4]. After 2 days of methotrexate injection the Foley's catheter was removed. There was no active bleeding. But next day patient started bleeding again. In view of ongoing bleeding and complete family with fertility not being a major issue, hysterectomy was planned to prevent life threatening bleeding in future. A review of medical treatment by Bij De Vaate *et al.* showed that 16/38 (42%) women had successful primary treatment with local or systemic methotrexate, 6/38 (16%) required major open surgery and 1/38(2. 6%) had a hysterectomy [14].

REFERENCES

1. Ash A, Smith A, Maxwell D. Caesarean scar pregnancy. BJOG: An International Journal of Obstetrics & Gynaecology. 2007 Mar 1;114(3):253-63.
2. Cheng PJ, Chueh HY, Soong YK. Sonographic diagnosis of a uterine defect in a pregnancy at 6 weeks' gestation with a history of curettage. Ultrasound in obstetrics & gynecology. 2003 May 1;21(5):501-3.
3. Fylstra DL. Ectopic pregnancy within a cesarean scar: a review. Obstetrical & gynecological survey. 2002 Aug 1;57(8):537-43.
4. Nawroth F, Foth D, Wilhelm L, Schmidt T, Warm M, Römer T. Conservative treatment of ectopic pregnancy in a cesarean section scar with methotrexate: a case report. European Journal of Obstetrics and Gynecology and Reproductive Biology. 2001 Nov 1;99(1):135-7.
5. Seow KM, Cheng WC, Chuang J, Lee C, Tsai YL, Hwang JL. Methotrexate for cesarean scar pregnancy after in vitro fertilization and embryo transfer. A case report. The Journal of reproductive medicine. 2000 Sep;45(9):754-7.
6. Jurkovic D, Hillaby K, Woelfer B, Lawrence A, Salim R, Elson CJ. First-trimester diagnosis and management of pregnancies implanted into the lower uterine segment Cesarean section scar. Ultrasound in obstetrics & gynecology. 2003 Mar 1;21(3):220-7.
7. Timor-Tritsch IE, Monteagudo A. Unforeseen consequences of the increasing rate of cesarean deliveries: early placenta accreta and cesarean scar pregnancy. A review. American Journal of Obstetrics & Gynecology. 2012 Jul 1;207(1):14-29.
8. Seow KM, Huang LW, Lin YH, Yan-Sheng Lin M, Tsai YL, Hwang JL. Cesarean scar pregnancy: issues in management. Ultrasound in obstetrics & gynecology. 2004 Mar 1;23(3):247-53.
9. Maymon R, Halperin R, Mendlovic S, Schneider D, Vaknin Z, Herman A, Pansky M. Ectopic pregnancies in Caesarean section scars: the 8 year experience of one medical centre. Human Reproduction. 2004 Feb 1;19(2):278-84.
10. Marchiole P, Gorlero F, De Caro G, Podesta M, Valenzano M. Intramural pregnancy embedded in a previous cesarean section scar treated conservatively. Ultrasound in Obstetrics & Gynecology. 2004 Mar 1;23(3):307-9.
11. Godin PA, Bassil S, Donnez J. An ectopic pregnancy developing in a previous caesarian section scar. Fertility and sterility. 1997 Feb 1;67(2):398-400.
12. Nawroth F, Foth D, Wilhelm L, Schmidt T, Warm M, Römer T. Conservative treatment of ectopic pregnancy in a cesarean section scar with methotrexate: a case report. European Journal of Obstetrics and Gynecology and Reproductive Biology. 2001 Nov 1;99(1):135-7.
13. Akbayir O, Gedikbasi A, Akyol A, Ucar A, Saygi-Ozyurt S, Gulkilik A. Cesarean scar pregnancy: a rare cause of uterine arteriovenous malformation. Journal of clinical ultrasound. 2011 Nov 1;39(9):534-8.

14. De Vaate AB, Huirne JA, Van Der Slikke JH, Schats R, Brölmann HA. Medical treatment of cesarean scar pregnancy. *Journal of minimally invasive gynecology*. 2010 Jan 1;17(1):133.