

## A cross - sectional study of the visual profile of pituitary macroadenomas in a tertiary health care

Lily Daniel<sup>1</sup>, Vaishnavi R<sup>2,\*</sup>, Bhagya Lakshmi M.V<sup>3</sup>, Ganesh K<sup>4</sup>

<sup>1</sup>Assistant Professor, Dept. of Ophthalmology, A.C.S. Medical College, Chennai, Tamil Nadu, <sup>2</sup>Senior Resident, <sup>3</sup>Post Graduate, Dept. of Ophthalmology, Sri Ramachandra Medical College & Research Institute, Chennai, Tamil Nadu, <sup>4</sup>Professor and HOD, Dept. of Neurosurgery, Sri Ramachandra Medical College & Research Institute, Chennai, Tamil Nadu, India

**\*Corresponding Author:**

Email: vaishnaviravi@gmail.com

### Abstract

Pituitary Macroadenoma, primarily a benign neurological condition initially may present to the Ophthalmologist with loss of vision. This cross sectional study in a Tertiary Health Care involved the analysis of the visual profile of 41 radiologically proven cases of pituitary macroadenomas. Simple visual function tests such as visual acuity, colour vision and visual field analysis by confrontation at the time of presentation followed by automated perimetry can raise a suspicion of pituitary tumours. Early detection favours a better visual prognosis. When patients present with relative afferent pupillary defect, optic disc pallor and extensive field loss, the visual prognosis is grave. It is important to diagnose pituitary adenomas in the early stages when a high index of suspicion can elicit a field defect. The classical field defect that has been described in pituitary tumours causing chiasmal compression is bitemporal hemianopia. The visual prognosis is best when the tumours are diagnosed even when they start producing a superior quadrantonopia before progressing to the classical bitemporal hemianopia.

**Keywords:** Bitemporal hemianopia, Pituitary macroadenomas, Superior bitemporal quadrantonopia, Visual signs, Visual prognosis.

### Introduction

The pituitary gland is lodged within the sella turcica which is a deep depression found on the superior surface of the body of sphenoid.<sup>1</sup> The pituitary gland can be affected by adenomas, Rathke cleft cysts and Craniopharyngiomas.<sup>2</sup> Pituitary gland can be also affected by inflammations, infections and vascular affections such as infarction and apoplexy.<sup>2</sup> The prevalence of pituitary adenomas amongst all pituitary tumours is 16.7%.<sup>3</sup> Pituitary tumours are classified as micro adenomas (less than 10 mm) and macroadenomas (more than 10mm) depending on their size.<sup>1</sup> As long as the tumours are microadenomas and intrasellar, the patient remains asymptomatic. When the size is more than 10mm, the diaphragma sella is breached and the stretching of pain sensitive fibres in the diaphragma sella causes headache.<sup>1</sup> Thus, headache in a patient with pituitary adenoma signifies suprasellar extension. Lateral extension of the tumour would cause invasion of the cavernous sinus and oculomotor palsy. A visual field defect is caused when the enlarging tumour impinges on the overlying optic chiasm or optic nerve.<sup>1</sup> Most of the cases of pituitary adenoma are diagnosed at the stage when the tumour produces bitemporal hemianopia or when there is gross loss of vision and the fundus examination shows optic disc pallor. The fact that colour vision, colour desaturation and visual field tests aid in the early pituitary adenomas cannot be overemphasized.

### Materials and Methods

A retrospective analysis of case records of 41 radiologically proven cases of pituitary macroadenomas

from a tertiary care hospital in South India from 2012 to 2015 was done. Patients above the age of eighty years, those with optic neuropathy resulting from other disorders such as glaucoma and those with retinal disorders such as diabetic and hypertensive retinopathy were excluded from the study. The ophthalmological assessment including best corrected visual acuity (BCVA), colour vision, visual field test by confrontation and automated perimetry (Humphrey, Dublin, CA, USA) were noted. The Swedish Interactive Threshold Algorithm (SITA FAST) or full threshold 30-2 was the algorithm used in the assessment of automated perimetry. Fundus examination was done by + 78 Diopter lens. The presence of relative afferent field defect (RAPD) was noted. The findings of radioimaging by magnetic resonance imaging (MRI) were reviewed. The initial visual presentation were correlated with the dimensions of the adenomas in MRI

**Statistical Analysis:** The statistical analysis was done following compilation of data using SPSS (version 16, IBM SPSS statistics). A p value of <0.05 was considered significant.

### Results

Total cases in our study were 41 of which 24 (58.5%) were males and 17 (41.5%) were females Table 1. The age at presentation revealed that maximum patients were in the age group of 41 to 60 years (46.3%). Headache was the commonest presenting symptom in 33 patients (80.5%). Blurred vision was the presenting symptom in 25 patients (61%). Visual field analysis by automated perimetry revealed that bitemporal hemianopia was the commonest visual field

defect in 21 patients (51.2%). of the 41 patients, 5 of them had normal visual fields and 11 had superior quadrantanopia. of the 11 of them who had superior quadrantanopia, 6 of them had bitemporal superior quadrantanopia and 5 had unocular superior quadrantanopia. There were 4 patients with visual acuity less than 6/24 with RAPD in their worst affected eye Table 2. The impaired colour vision and RAPD was more in females which was significant statistically ( $p < 0.05$ ) Table 3.

The maximum diameter of the adenoma for patients with normal fields was within 16mm on MRI. The corresponding diameter of the macroadenoma for patients presenting with superior quadrantanopia was between 17 mm and 29 mm. The cases that presented with bitemporal hemianopia had corresponding MRI dimensions of more than 30 mm, all displacing the optic chiasm. The 8 patients who presented with signs of oculomotor palsy had extension of the adenoma into the cavernous sinus, encasing the internal carotid arteries on either side in 3 patients (Knosp grade 4).

Of the 41 cases of pituitary macroadenomas, 9 were found to be prolactinomas Table 4. 1 was adrenocorticotrophic hormone secreting and 1 was growth hormone producing. Of the 9 cases of prolactinomas, 5 were males and 4 were females. The male patients with prolactinomas also had associated Hypothyroidism. 2 of the cases of Prolactinoma did not undergo surgery as there was significant reduction in the size of the tumour and corresponding visual field recovery after medical therapy. 26 underwent trans sphenoidal excision of the adenoma through the transnasal endoscopic route, 2 through the sublabial route. Of the 11 patients who had superior quadrantanopia, 9 of them had complete recovery of fields. The visual field changes of bitemporal hemianopia were persistent in various degrees after surgery in those patients who had presented with RAPD, impaired colour vision and pallor of the disc.

## Discussion

The male preponderance in our study is comparable to earlier studies by Fernandez A et al.<sup>4</sup> The age at presentation is similar to the community based study conducted by Fernandes A et al<sup>4</sup> and Antii Raappana et al<sup>5</sup> 80% of patients in our study presented with headache. Jackson et al<sup>6</sup> had reported an incidence of 68.8% incidence of headache in a study group of 64 patients. Headache in pituitary adenomas has been attributed to stretching of the duramater and increased intra sellar pressure.<sup>6</sup> Lateral expansion into cavernous sinus also causes headache.<sup>7</sup> While 11 of the patients had superior quadrantanopia, 21 patients had already progressed to bitemporal hemianopia before being diagnosed to have pituitary macroadenoma. Chiasmatic

compression is characterised by bitemporal hemianopia<sup>8</sup> Bitemporal hemianopia as the commonest visual field defect in pituitary adenomas has also been reported by Alexander et al<sup>9</sup> and Huang WC et al.<sup>10</sup> Huang WC et al had demonstrated a linear relationship between visual field defect and chiasmatic compression. He also concluded that the visual field defects were more dense in non secreting adenomas. Lee et al in a study of 119 patients, found bitemporal hemianopia was more common in patients whose MRI showed a displacement of the optic pathway of more than 3 mm from the baseline.<sup>11</sup> Simple visual function tests like finger confrontation tests and colour desaturation at the outpatient services can easily elicit a visual field defect. Trobe JD et al<sup>12</sup> had established that static finger counting tests had elicited 42% of chiasmatic hemianopic defects. He concluded that kinetic and static colour confrontation tests were 78.6% sensitive to hemianopias.

The swinging torch light test elicits RAPD and signifies optic neuropathy which in these cases is compressive. Decreased visual acuity, associated with impaired colour vision and RAPD in the worse affected eye, temporal pallor of the optic nerve head, all are signs of Compressive Optic neuropathy. These signs are more common when the chiasm is post fixed.<sup>1</sup> MRI of the brain is the imaging modality of choice in the diagnosis of pituitary tumours. Knosp grading system grades the cavernous sinus involvement of the pituitary adenomas.<sup>13</sup> The magnetizing transfer ratio differentiates secretory tumours from non secreting tumours.<sup>14</sup> Hormonal assay identifies the secretory nature of pituitary tumours. Prolactinomas more commonly are known to occur in females between 20 – 50 years.<sup>15</sup> In our study, of the 9 patients diagnosed with prolactinomas, 5 were males.

The surgical management of pituitary macroadenomas is Resection via the transnasal endoscopic sphenoidal route. Ren – Wen Ho reported good visual prognosis when adenectomy was performed in pituitary adenomas that were less than 20mm in diameter.<sup>16</sup>

There have been studies that have analysed the type of field defects in pituitary adenomas. To the best of our knowledge, this is the first study that has analysed all the visual signs in pituitary macroadenomas. The limitation of our study was that it was a retrospective study. A prospective study with standardized protocols and comparison of the presenting signs with the volumetric 3dimensional analysis of pituitary adenomas in MRI would throw further light in understanding the presentation and progression of these tumours.

**Table 1: Socio- demographic profile of the subjects**

Variable(Classification of variable)	Number	Percentage
Age		
21-40 years	10	24.4
41- 60 years	19	46.3
> 60 years	12	29.3
Gender		
Male	24	58.5
Female	17	41.5

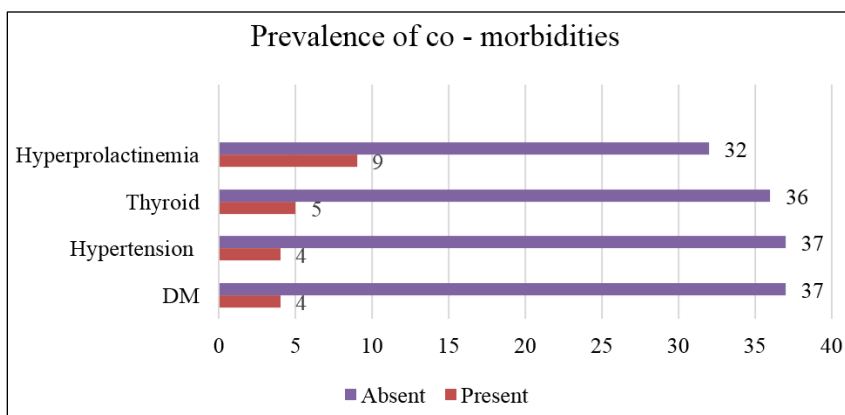
**Table 2: Profile symptoms and signs among the subjects**

Variable	Number	Percentage	95% C.I
Headache	33	80.5	68.37% to 92.63%
Blurred vision	25	61	46.07% to 75.93%
Visual Acuity in the worse eye			
6/6 – 6/12			
6/18 – 6/24	16	39	24.07% to 53.93%
6/36 - 6/60	21	51.3	36% to 66.6%
< 6/60	1	2.4	-2.28% to 7.08%
	3	7.3	-0.66% to 15.26%
Visual fields			
Normal	5	12.2	2.18% to 22.22%
Superior Quadrantanopia	11	26.8	13.24% to 40.36%
Bi-temporal hemianopia	21	51.2	35.9% to 66.5%
Complete visual loss	4	9.8	0.7% to 18.9%
RAPD	14	34.1	19.59% to 48.61%
Colour vision affected	15	36.6	21.86% to 51.34%
Oculomotor palsy	8	19.5	7.37% to 31.63%

**Table 3: Association between the signs and symptoms of pituitary adenoma and gender**

Presentation	Male (out of 24)	Females (out of 17)	Odds ratio (95% C.I of odds ratio)	Chi –square value	P value
Headache (M)	20	13	1.54(0.33-7.26)	0.02	0.88
Blurred vision (M)	15	10	1.67( 0.33 – 4.16)	0.00	1.00
RAPD (F)	5	9	4.28 ( 1.09 – 16.83)	4.45	0.035 *
Colour vision affected (F)	5	10	5.43(1.37 – 21.58)	6.04	0.014 *
Paresis (F)	3	5	2.92 ( 0.59 – 14.41)	0.90	0.34

(\* - Statistically significant)

**Fig. 1**

## Conclusion

Headache is the most common presenting symptom followed by blurred vision. Pituitary macroadenomas are often diagnosed late with the onset of visual loss and field defects most frequently bitemporal hemianopia. It is very important to diagnose the disease at the stage when it produces superior quadrantanopia rather than when it progresses to bitemporal hemianopia. The presence of RAPD, impaired coloured vision, temporal pallor of the optic nerve head are poor prognostic indicators for visual recovery after surgical resection of these macroadenomas.

**Acknowledgement:** The Department of Neurosurgery, Sri Ramachandra Medical Centre, Porur, Chennai 600116, India. Dr. Christina Mary Paul, Professor of Community Medicine, A.C.S Medical College for the statistical interpretations.

## References

1. Kanski's Clinical Ophthalmology. A systematic approach. 8<sup>th</sup> Ed. Elsevier. In. Neurophthalmology. p 813-815
2. Imaging of the sella: anatomy and pathology. Elster AD, Semin Ultrasound CT MR. 1993;14(3):182-94.
3. Ezzat S, Asa SI, Couldwell WT, Barr CE, Dodge WF, Vance MI *Et al*: The prevalence of pituitary adenomas: a systematic review. *Cancer* 2004;101:613-619.
4. Fernandez A, Karavitaki N, Wass JA. Prevalence of pituitary adenomas: a community-based, cross-sectional study in Banbury (Oxfordshire, UK). *Clin Endocrinol (Oxf)*. 2010;72(3):377-82.
5. Raappana A, Koivukangas J, Ebeling T, Pirilä T. Incidence of pituitary adenomas in Northern Finland in 1992-2007. *J Clin Endocrinol Metab*. 2010;95(9):4268-75.
6. Jackson A, Gondim AE, Joaõ Paulo Cavalcante de Almeida. Headache associated with pituitary tumors. *J Headache Pain*. 2009;10:15-20.
7. Jean-Philippe Cottier, Christophe Destrieux, Laurent Brunereau, Philippe Bertrand. Cavernous Sinus Invasion by Pituitary Adenoma: MR Imaging. *radiology*. 2000;215(2):463-9.
8. Munoz Negrete FZ, Rebelleda G. Automated perimetry and neurophthalmology, topographic correlation, *rch soc Esp Oftalmol* 2002;77(8):413-28.
9. Poon A, McNeill P, Harper A, O'Day J. Patterns of visual loss associated with pituitary Macroadenomas. *Aust N Z J Ophthalmol*. 1995. 23(2):107-15.
10. Huang WC<sup>1</sup>, Lee LS. Visual field defects in patients with pituitary adenomas. *Zhonghua Yi Xue Za Zhi (Taipei)*. 1997;60(5):245-51.
11. Lee IH, Miller NR, Zan E, Tavares F, Blitz AM, Sung H, Yousem DM, Boland MV. Visual Defects in Patients With Pituitary Adenomas: The Myth of Bitemporal Hemianopsia. *AJR Am J Roentgenol*. 2015; 205(5):W512-8.
12. Trobe JD, Acosta PC, Krischer JP, Trick GL. Confrontation visual field techniques in the detection of anterior visual pathway lesions. *Ann Neurol*. 1981;10 (1):28-34.
13. Mooney MA, Hardesty DA, Sheehy JP, Bird R, Chapple K, White WL, Little AS. Interrater and intrarater reliability of the Knosp scale for pituitary adenoma grading. *Neurosurg*. 2017;126(5):1714-1719.
14. Chaudhary V, Bano S. Imaging of the pituitary: Recent advances. *Indian J Endocrinol Metab*. 2011;15 Suppl 3:S216-23.
15. Ciccarelli A, Daly AF, Beckers A. The epidemiology. Of Prolactinomas. *Pituitary*. 2005;8(1):3-6.
16. Ho RW, Huang HM, Ho JT. The influence of pituitary adenoma size on vision and visual outcomes after trans-sphenoidal adenectomy: a report of 78 cases. *J Korean Neurosurg Soc*. 2015;57(1):23-31.